

Case Report

# An unusual case of anteroinferior paralabral cyst with axillary nerve compression: A case report

Arun G. Ramaswamy<sup>1</sup>, Neelanagowda Police Patil<sup>1</sup>, Namrata Srinivasan<sup>1</sup>

<sup>1</sup>Department of Orthopaedics, Mysore Medical College and Research Centre, Mysore, Karnataka, India.

## ABSTRACT

Paralabral cysts are an uncommon cause of shoulder pain in young adults. Their association with neurological symptoms is seldom reported in the literature. The cysts are believed to develop when there is a labral tear allowing synovial fluid entry into tissues causing one-way valve effect. This case report describes a case of anteroinferior paralabral cyst in a painful shoulder associated with axillary nerve palsy. MRI revealed an anteroinferior labral cyst. Electromyography revealed denervation of deltoid and teres minor muscles. Shoulder arthroscopy was performed with cyst decompression and labral repair. Shoulder function improved gradually and by the end of 1 year, power was back to pre-injury status. Paralabral cysts are a rare entity. When associated with nerve injury, prompt decompression is necessary to prevent irreversible nerve and muscle damage.

**Keywords:** Labral cyst, Axillary nerve, Cyst decompression

## INTRODUCTION

Paralabral cysts are an uncommon cause of shoulder pain in young adults.<sup>[1]</sup> The incidence is around 2–4% in general population.<sup>[2]</sup> The site of occurrence is 57% in posterior labrum, 21% in anterior labrum, 14% in superior labrum, and 8% in inferior labrum.<sup>[3]</sup> Their association with neurological symptoms are seldom reported in the literature. The cysts are believed to develop when there is a labral tear allowing synovial fluid into tissues causing one-way valve effect.<sup>[4]</sup> This case report describes a case of anteroinferior paralabral cyst in a painful shoulder associated with axillary nerve palsy.

## CASE REPORT

A 24-year-old male had a history of fall at his residence following which he sustained injury to the left shoulder. Mechanism of injury was a direct blow to shoulder in awkward position with no dislocation. He had pain and difficulty in abduction along with painful shoulder movements with weakness. X-ray was grossly normal and the patient was managed conservatively with rest and medication for the time being.

The patient presented to us in the outpatient department 6 months later, with complaints of persistent pain and restriction of movements in the left shoulder. On examination, the patient had tenderness over anterior aspect

of shoulder and decreased sensations over deltoid muscle. The patient had restriction of overhead abduction, external rotation, and mild restriction of flexion at elbow. Elbow flexion was restricted as a protective mechanism to reduce shoulder movements. There was no musculocutaneous nerve involvement, which was confirmed clinically and with nerve conduction study. Wasting of deltoid muscle was noted. Cervical spine examination was normal and neurological examination revealed wasting of posterior deltoid muscles and loss of sensation over lateral arm.

Magnetic resonance imaging revealed anteroinferior labral tear with large multiloculated paralabral cyst caudal to inferior glenoid rim [Figure 1]. The patient was diagnosed to have a compression neuropathy of axillary nerve by the large cyst, which was confirmed by nerve conduction study. The axillary nerve lies closest to infraglenoid rim with a distance of 12 mm from inferior glenoid. Only a large cyst can compress the nerve leading to neuropathy as described in our scenario.

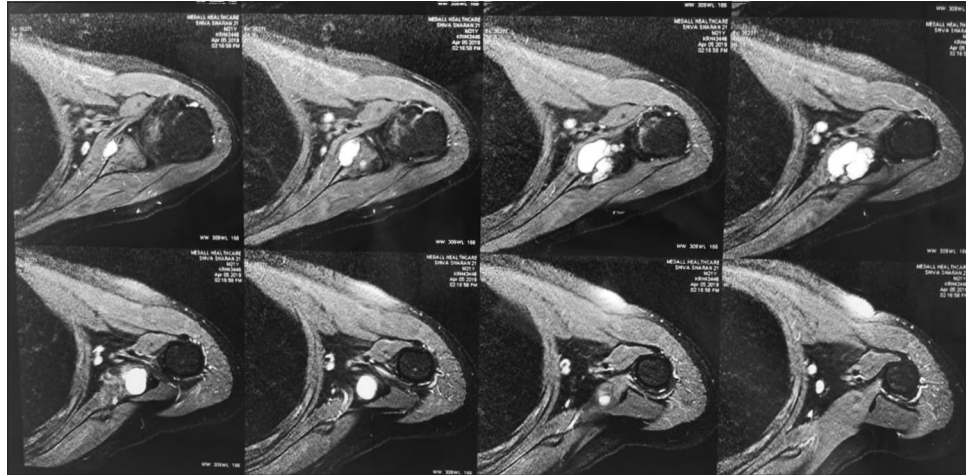
## Surgical procedure

The patient was placed in lateral position under general anesthesia. With posterior portal, diagnostic arthroscopy was done. Anterosuperior and anteroinferior portals were made. Anteroinferior labral tear was confirmed. Cystic fluid

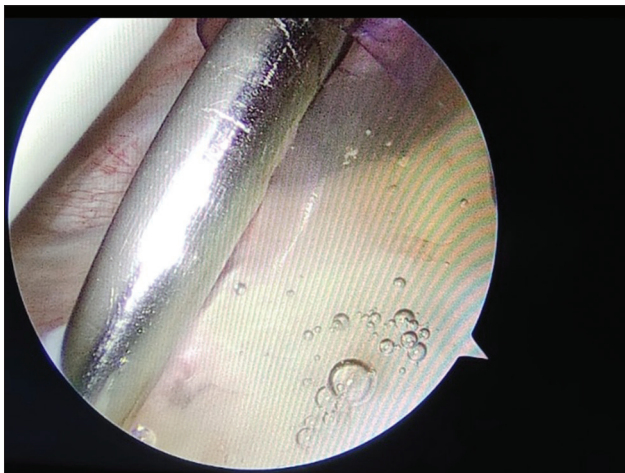
\*Corresponding author: Arun G Ramaswamy, Department of Orthopaedics, Mysore Medical College and Research Centre, Mysore, Karnataka, India. drgraran@gmail.com

Received: 28 April 2021 Accepted: 01 November 2021 Epub Ahead of Print: 23 November 2021 Published: 20 December 2021 DOI: 10.25259/JASSM\_18\_2021

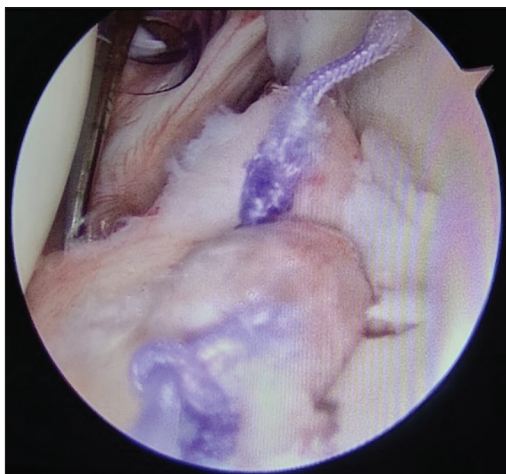
This is an open-access article distributed under the terms of the Creative Commons Attribution-Non Commercial-Share Alike 4.0 License, which allows others to remix, tweak, and build upon the work non-commercially, as long as the author is credited and the new creations are licensed under the identical terms. ©2022 Published by Scientific Scholar on behalf of Journal of Arthroscopic Surgery and Sports Medicine



**Figure 1:** MRI of shoulder showing cyst in anteroinferior region.



**Figure 2:** Arthroscopic drainage of Cyst fluid.



**Figure 3:** Repair of the labrum with suture anchors.

was drained to achieve decompression followed by resection of cyst walls with arthroscopic shaver and the labral tear was repaired with suture anchors [Figure 2].

### Post-operative rehabilitation

Post-operative period was uneventful. The patient reported decrease in shoulder pain shortly after the procedure. The shoulder was immobilized for 6 weeks with gentle elbow movements. Gradually, shoulder mobilization was started. A clinical evaluation at 12 months after surgery showed complete recovery of active movements at shoulder with Grade 5 power [Figure 3].

### DISCUSSION

Inferior paralabral cysts are very rare presentations with an estimated incidence of 0.6% and are usually associated with labral tears most commonly occurring in young active males.<sup>[5]</sup> Suprascapular nerve entrapment is a cause of shoulder pain and weakness. Suprascapular compression neuropathy is infrequent, causing only 1–2% of shoulder pain.<sup>[6]</sup> Evidence of anterior or inferior paralabral cysts with axillary nerve compression neuropathy has not been documented. Park *et al.* reported a case of compression neuropathy of the axillary nerve caused by an anteroinferior paralabral cyst in a young basketball player.<sup>[7]</sup> There was no history of trauma. The patient was relieved with activity modification and rest. Paraglenoid cysts are frequently anterior, posterior, superior, and rarely inferior.<sup>[4]</sup> Cases of paralabral cysts with associated neurological symptoms are extremely rare. Early identification and aggressive treatment should be the priority to prevent irreversible nerve damage and muscle atrophy. Our approach in this case report was to decompress the paralabral cyst and repair the labral lesion as anatomic repair prevents shoulder instability and cyst recurrence. Knowledge of this condition and its MRI features is crucial for correct diagnosis and management.

### CONCLUSION

This case report reinforces the importance of an accurate early clinical examination and MRI evaluation in patients

with shoulder pain in concurrence with neurological symptoms. When identified, paralabral cyst can be successfully treated by shoulder arthroscopy and recurrence can be avoided.

#### **Declaration of patient consent**

The authors certify that they have obtained all appropriate patient consent.

#### **Financial support and sponsorship**

Nil.

#### **Conflicts of interest**

There are no conflicts of interest.

#### **REFERENCES**

1. Klumpp R, Gallinari G, Compagnoni R, Trevisan C. Antero-inferior paralabral cyst of the shoulder: An atypical cause of rapidly evolving

- axillary and musculocutaneous nerve palsy. *J Clin Orthop Trauma* 2020;11 Suppl 4:S681-3.
2. Gartsman GM. *Shoulder Arthroscopy*. 2<sup>nd</sup> ed. Philadelphia, PA: WB Saunders; 2008.
3. Westerheide KJ, Dopirak RM, Karzel RP, Snyder SJ. Supra-scapular nerve palsy secondary to spinoglenoid cysts: Results of arthroscopic treatment. *Arthroscopy* 2006;22:721-7.
4. Iannotti JP, Ramsey ML. Arthroscopic decompression of a ganglion cyst causing suprascapular nerve compression. *Arthroscopy* 1996;12:739-45.
5. Jeong JJ, Panchal K, Park SE, Kim YY, Lee JM, Lee JK, *et al.* Outcome after arthroscopic decompression of inferior labral cysts combined with labral repair. *Arthroscopy* 2015;31:1060-8.
6. Boykin RE, Friedman DJ, Higgins LD, Warner JJ. Suprascapular neuropathy. *J Bone Joint Surg Am* 2010;92:2348-64.
7. Park JY, Jeon SH, Oh KS, Chung SL, Jung-Joo B, Bang JY. Compressive partial neuropathy of axillary nerve resulting from antero-inferior paralabral cyst in an adolescent overhead athlete. *Korean J Sports Med* 2015;33:1054547.

**How to cite this article:** Ramaswamy AG, Patil NP, Srinivasan N. An unusual case of anteroinferior paralabral cyst with axillary nerve compression: A case report. *J Arthrosc Surg Sports Med* 2022;3:50-2.