

Arthroscopic Techniques

Ease of femoral tunnel preparation through transportal pathway – A technical note

Sai Krishna M L V¹, Hira L. Nag¹, Anupam Gupta¹

¹Department of Orthopaedics, AIIMS, New Delhi, India.

ABSTRACT

Accurate femoral tunnel placement is a crucial step in Anterior Cruciate Ligament (ACL) reconstruction and non-anatomical placement of the tunnel may result in rotational instability. With advancements in arthroscopic techniques and to achieve better rotational stability, femoral tunnel placement has changed from the transtibial technique to the transportal method. Identification of ACL footprint is the foremost step during transportal drilling. In this technical note, we describe an easy way to the identification of the femoral footprint to drill the femoral tunnel during the transportal method.

Keywords: ACLR, Femoral tunnel, Transportal technique, Clock face technique

INTRODUCTION

Accurate femoral tunnel placement is a crucial step in Anterior Cruciate Ligament (ACL) reconstruction and non-anatomical placement of the tunnel may result in rotational instability, and graft impingement with the roof of the notch or posterior cruciate ligament and graft fiber tension mismatch.^[1] This may result in graft failure or dysfunction leading to the persistence of instability.

With advancements in arthroscopic techniques and to achieve better rotational stability, femoral tunnel placement has changed from the transtibial technique to the transportal method. Identification of ACL footprint is the foremost step during transportal drilling. The femoral attachment is on the medial surface of the lateral femoral condyle and various methods are described for identifying the same including the clock face method and the osseous landmarks such as bifurcate and resident ridges.^[1] Interchanging the diagnostic portal and working portal also influences the identification of femoral footprint for tunnel drilling as is the degree of knee flexion. In this technical note, we describe an easy way to the identification of the femoral footprint to drill the femoral tunnel during the transportal method.

SURGICAL TECHNIQUE

With the patient in the supine position and inflating the pneumatic tourniquet placed on the proximal thigh, diagnostic arthroscopy is conducted with standard anterolateral and

anteromedial portals. The anterolateral portal is made in the soft spot lateral to the patellar tendon and inferolateral to the inferior pole of the patella, whereas the anteromedial portal is made medial to the patellar tendon and above the joint line. The anteromedial portal is confirmed with the help of a 18G venflon needle through the landmark as described above with an arthroscope in the anterolateral portal such that the needle enters the capsule above the medial meniscus and aims at the medial surface of the lateral femoral condyle. After confirmation of the diagnosis, both the hamstring tendons including gracilis and semitendinosus are harvested and quadrupled over an Endobutton CL (Smith and Nephew, Andover, MA) as a fixation device for the femoral side. With the arthroscope in the anterolateral portal and shaver in the anteromedial portal, the medial side of the lateral femoral condyle is cleaned followed [Figure 1] by notchplasty if required, the arthroscope gives the tangential view of the medial surface of the lateral femoral condyle. Using a bent-tip ablator, 3 mm diameter (Cool Cut Ablator, 3 mm, 90°, Arthrex, Naples, Florida) a mark is created on the medial surface of the lateral femoral condyle at 90° knee flexion. This mark is placed at 10.30 clock position on the right knee or 1.30 clock position for the left knee and anterior to posterior condyle (over the top reference) with a distance equivalent to two ablator diameters [Figures 2-4]. Once the marking is done, a standard Arthrex femoral transportal offset of 6 mm is used, which we routinely use for hamstring tendon graft, where the

*Corresponding author: Anupam Gupta, Department of Orthopaedics, AIIMS, New Delhi, India. anupam1054@yahoo.com

Received: 28 February 2022 Accepted: 01 June 2022 Epub Ahead of Print: 22 June 2022; Published: 21 September 2022 DOI: 10.25259/JASSM_9_2022

This is an open-access article distributed under the terms of the Creative Commons Attribution-Non Commercial-Share Alike 4.0 License, which allows others to remix, transform, and build upon the work non-commercially, as long as the author is credited and the new creations are licensed under the identical terms. ©2022 Published by Scientific Scholar on behalf of Journal of Arthroscopic Surgery and Sports Medicine

average diameter of the graft is between 6.5 and 8 mm, which rests on the articular surface of the posterior lateral condyle through the anteromedial portal with a knee in full flexion [Figure 5]. The ablator mark helps with the accurate coronal or clock face orientation to identify the ACL footprint for drilling the guidewire [Figures 4 and 6], which is otherwise difficult to visualize in extreme knee flexion. Once the guidewire is placed, a standard entry reamer is used of size 4.5 mm followed by the tunnel length which is measured. In all of our cases, the average tunnel length is between 35 and 40 mm. Later, the femoral tunnel is prepared with consecutive reamers in accordance with the graft diameter. Subsequently, the tibial tunnel is drilled using the ACL stump and the posterior border of the anterior horn of the lateral meniscus as the landmarks. The graft is secured with an Endobutton CL (Smith and

Nephew, Andover, MA) over the femoral side and bioscrew (Smith and Nephew, Andover, MA) on the tibial side.

DISCUSSION

The femoral tunnel can be drilled either transportally, transtibially, or from the outside-in pathway. The transtibial preparation of the femoral tunnel results in a vertical tunnel high in the notch which might result in rotational instability. The anatomical femoral tunnel placement closer to the native femoral footprint can be done through a transportal pathway or outside in path and results in a rotationally stable knee. Transportal drilling can be done either with

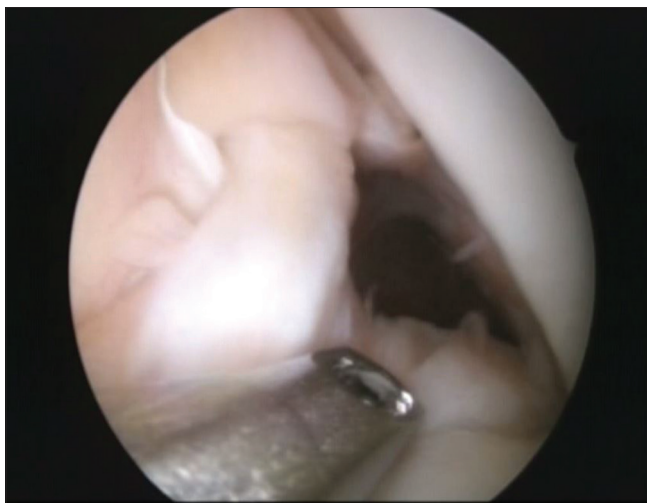

Figure 1: Tangential orientation of the lateral femoral condyle with arthroscope in the anterolateral portal and shaver tip through the anteromedial portal.

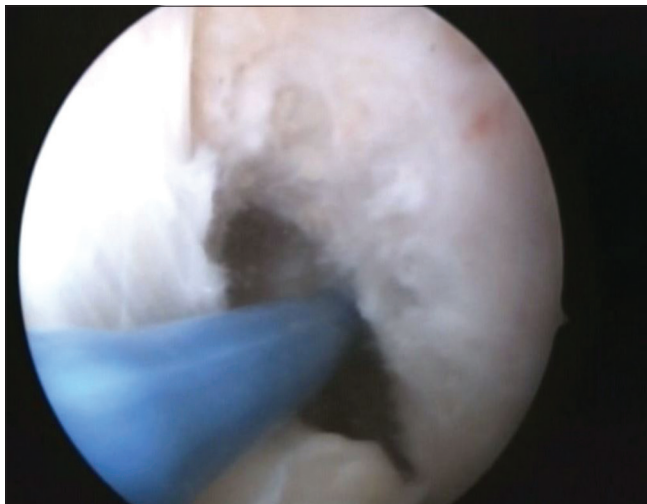


Figure 2: A 3 mm, 90° bent cool cut ablator tip using the posterior condyle as a reference, over the top approach.

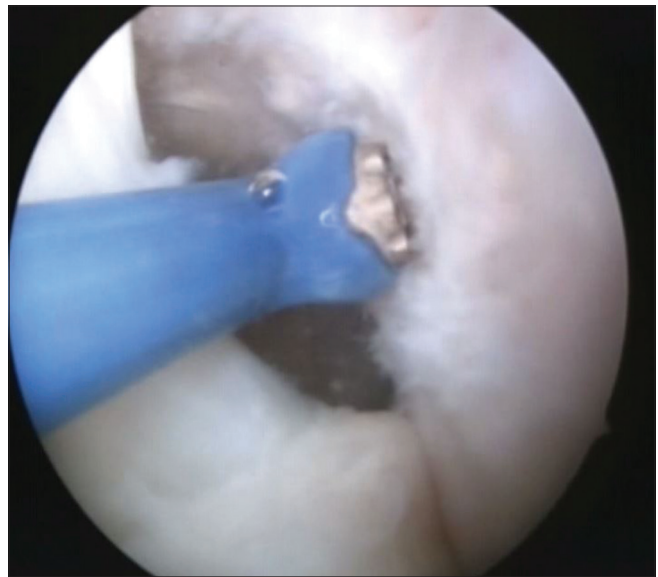

Figure 3: The ablator using the posterior condylar articular surface is translated anteriorly through two ablator diameters and marked using the clock face technique on the medial surface of the lateral femoral condyle.

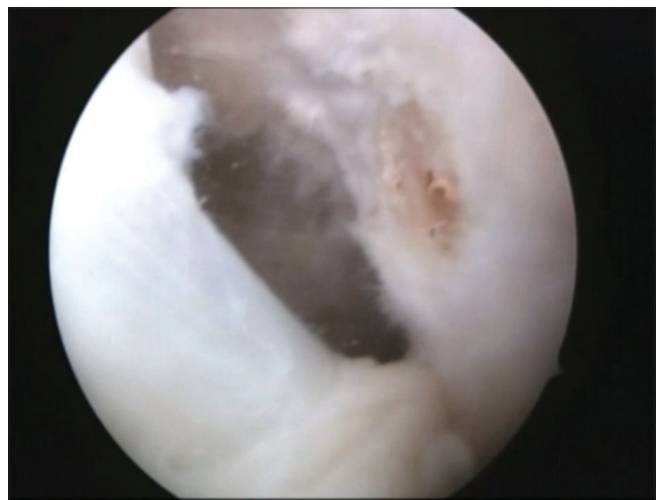


Figure 4: The mark being seen on the medial surface of the lateral femoral condyle which gives us the clock face orientation.

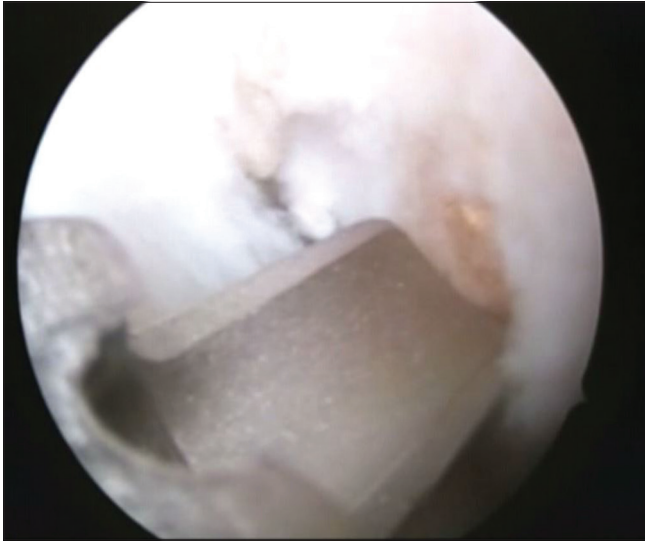

Figure 5: The 6 mm arthrex transportal offset resting on the ablator mark.

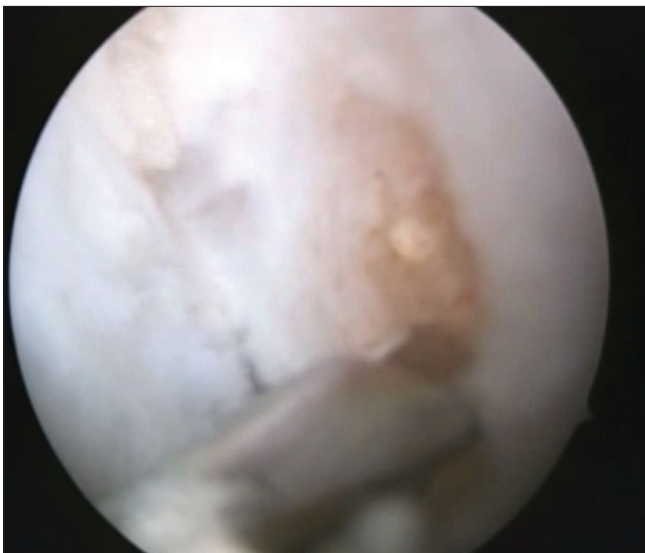


Figure 6: The drill wire passing through the offset resting on the ablator mark, with offset providing the anteroposterior landmark and the ablator mark giving us the coronal/craniocaudal/clock face orientation.

an anteromedial portal or an accessory anteromedial portal. When the femoral tunnel is drilled using either the accessory anteromedial portal or the outside path, the standard anteromedial portal can be used as a diagnostic portal. This gives an orthogonal view of the femoral condyle. When the anteromedial portal is employed as the working portal, the diagnostic portal is anterolateral, and this gives a tangential view of the medial surface of the lateral femoral condyle [Figure 1]. Precise placement of femoral tunnel necessitates correct identification of anatomical ACL footprint. This requires measurements in

both the anteroposterior axis (shallow/deep with respect to the posterior condylar articular surface) as well as the craniocaudal axis (high/low with respect to the inferior articular surface).^[1,2] It can be done using a ruler, an offset, using the clock face technique, or anatomical landmarks.^[1-3] In this technical note, we describe an easy way of femoral tunnel preparation while using only standard anteromedial and anterolateral portals without employing an accessory medial portal. We used anterolateral as the diagnostic portal and anteromedial as the working portal. Orientation in the craniocaudal axis is based on the clock face method using an ablator-mark with the knee in 90° flexion [Figures 3 and 4]. Once the mark is placed, a 6 mm. Arthrex transportal offset is placed from the anteromedial portal with the offset resting on the posterior lateral condylar articular surface through the notch with the knee in full flexion. The ablator mark provides orientation in the craniocaudal axis [Figure 4] or the coronal plane, whereas the offset resting on the posterior articular surface provides the anterior-posterior axis or sagittal plane coordinate for unerring placement of the tunnel [Figures 5 and 6]. Increasing knee flexion and using an anteromedial portal provides maximal coronal obliquity and addresses the concerns of rotational stability.^[4] However, at the same time, full knee flexion makes identification of footprint from the anteromedial portal cumbersome. In our technique, we marked the coronal plane identifier at 90° knee flexion at an approximate distance of 5–7 mm from the posterior articular surface using a bent-tip ablator only as a distance guide [Figures 2-4]. Once the coronal coordinate is marked, we use the transportal offset from the anteromedial portal with the knee in full flexion for identifying the sagittal plane coordinate [Figure 5]. With offset placed through the anteromedial portal resting on the posterior articular surface with the knee in full flexion, we use the ablator mark for drilling the femoral tunnel [Figures 4 and 6]. Hence, this technique offers explicit identification of both sagittal and coronal plane coordinates of the anatomic ACL footprint while allowing preparing the tunnel in full knee flexion which helps in achieving coronal obliquity as well as maximum tunnel length without the need for creating an accessory medial portal or using an outside-in technique.

CONCLUSION

Identification of ACL footprint is the foremost step during trans-portal drilling. In this technical note we described an easy way for the identification of the sagittal and coronal coordinates of the femoral footprint via transportal technique.

Declaration of patient consent

Patient's consent not required as patients identity is not disclosed or compromised.

Financial support and sponsorship

Nil.

Conflicts of interest

There are no conflicts of interest.

REFERENCES

1. Robinson J, Inderhaug E, Harlem T, Spalding T, Brown CH Jr. Anterior cruciate ligament femoral tunnel placement: An analysis of the intended versus achieved position for 221 international high-volume ACL surgeons. *Am J Sports Med* 2020;48:1088-99.
2. Bedi A, Raphael B, Maderazo A, Pavlov H, Williams RJ 3rd. Transtibial versus anteromedial portal drilling for anterior cruciate ligament reconstruction: A cadaveric study of femoral tunnel length and obliquity.

Arthroscopy 2010;26:342-50.

3. Gadikota HR, Sim JA, Hosseini A, Gill TJ, Li G. The relationship between femoral tunnels created by the transtibial, anteromedial portal, and outside-in techniques and the anterior cruciate ligament footprint. *Am J Sports Med* 2012;40:882-8.
4. Arno S, Bell CP, Alaia MJ, Singh BC, Jazrawi LM, Walker PS, *et al.* Does anteromedial portal drilling improve footprint placement in anterior cruciate ligament reconstruction? *Clin Orthop Relat Res* 2016;474:1679-89.

How to cite this article: Sai Krishna MLV, Nag HL, Gupta A. Ease of femoral tunnel preparation through transportal pathway – A technical note. *J Arthrosc Surg Sports Med* 2022;3:120-3.