

Review Article

Fifth metatarsal fractures: Review of the current concepts

Amr Eldessouky¹, Maneesh Bhatia¹

¹Department of Trauma and Orthopaedics, University Hospitals of Leicester NHS Trust, Leicester, United Kingdom.

ABSTRACT

Fractures of the fifth metatarsal are among the most common injuries in the foot, often presenting significant challenges for treatment, particularly when they occur at the base. This area is especially problematic due to its unique blood supply, which can result in delayed or non-union. The treatment of these fractures has been a subject of extensive debate among surgeons for many years. Various treatment approaches have been proposed, reflecting differing opinions on the best methods to ensure optimal patient outcomes. This review offers a comprehensive overview of the anatomy, classifications, and mechanisms of injury. It also discusses the different non-operative and operative approaches and highlights the latest concepts in managing fifth metatarsal fractures. The review offers valuable insights for clinicians, helping them choose the most effective treatment protocols based on the fracture type and the patient's level of activity and needs.

Keywords: Fifth metatarsal, Fractures, Foot, Jones fracture, Stress fractures

INTRODUCTION

Fifth metatarsal fractures are the most frequently occurring metatarsal fractures. Their incidence in men peaks in the third decade of life, while in women, it peaks in the sixth decade.^[1] The location of fifth metatarsal fractures has been an area of interest due to the unusual blood supply, particularly at the base, which can contribute to delayed union and non-union.^[2] Various classifications have been proposed, primarily based on the fracture's location. The term "Jones fracture," first described by Sir Robert Jones, refers to fractures at the metaphyseal-diaphyseal junction.^[3]

The optimal treatment for these fractures has been a subject of controversy. In addition to the fracture's location, other factors influencing treatment options include the patient's age, activity level, and bone quality. Failure to properly treat these fractures can significantly impact patients' quality of life. Some studies advocate for surgical fixation, especially in athletes, to prevent delayed union and non-union and to facilitate an early return to sports.^[4,5] Conversely, other studies recommend non-operative treatment due to its favorable outcomes and the avoidance of surgical complications.^[6] This literature review aims to provide a comprehensive overview of current concepts on the management of fifth metatarsal fractures and identify areas for future research.

ANATOMY

Understanding the anatomy of the fifth metatarsal bone and its soft-tissue attachments is crucial for diagnosing fractures and determining treatment. The fifth metatarsal supports the lateral longitudinal and transverse arches, which distribute foot stress and enable efficient propulsion during walking and running. Soft-tissue attachments, including the peroneus brevis, peroneus tertius muscles, lateral plantar aponeurosis band, and long plantar ligament, contribute to zone 1 fractures through traction stress.^[7,8]

DeVries' cadaveric study identified three zones at the proximal end of the fifth metatarsal based on attachment sites of the peroneus brevis and plantar fascia.^[9] Other biomechanical studies have shown that peroneus brevis tendon contraction affects fracture stability, particularly in those distal to its insertion.^[10]

The blood supply to the fifth metatarsal includes the metaphyseal, periosteal, and nutrient arteries. A fracture at the proximal diaphysis can disrupt the nutrient artery, leading to delayed or non-union due to avascularity.^[2] The sural nerve, running near the fifth metatarsal base, is at risk during intramedullary (IM) fixation. Fansa *et al.* recommend a "high and inside" approach to avoid injuring the lateral dorsal cutaneous branch of the sural nerve.^[11]

*Corresponding author: Amr Eldessouky, Department of Trauma and Orthopaedics, University Hospitals of Leicester NHS Trust, Leicester, United Kingdom. amr_rbc@yahoo.com

Received: 01 August 2024 Accepted: 21 October 2024 Epub Ahead of Print: 18 November 2024 Published: XXXXXX DOI: 10.25259/JASSM_34_2024

This is an open-access article distributed under the terms of the Creative Commons Attribution-Non Commercial-Share Alike 4.0 License, which allows others to remix, transform, and build upon the work non-commercially, as long as the author is credited and the new creations are licensed under the identical terms. ©2024 Published by Scientific Scholar on behalf of Journal of Arthroscopic Surgery and Sports Medicine

CLASSIFICATIONS

Since Sir Robert Jones first described fractures at the metaphyseal-diaphyseal junction, the term “Jones fracture” has been used broadly to describe other proximal metatarsal fractures, leading to considerable confusion. To address this, several classifications have since been developed to more precisely define the location and pattern of these fractures. Stewart’s 1960 classification divides fractures into five zones based on location and morphology.

Torg, in 1984, developed a classification for fractures at proximal diaphysis based on the radiological appearance and fracture age:

Type I (acute): Fracture with a narrow fracture line and no IM sclerosis.

Type II (delayed union): Characterized by wide fracture line and IM sclerosis.

Type III (non-union): Represents complete obliteration of the medullary canal by sclerotic bone.^[12]

One of the most used classifications nowadays for proximal fifth metatarsal fractures was introduced by Lawrence and Botte in 1993.^[13] This classification categorizes fractures into three types based on the mechanism of injury, fracture location, management, and prognosis:

Zone 1 “Avulsion tuberosity fractures”

These are avulsion fractures of the tuberosity caused by the forces exerted by the peroneus brevis tendon or, more commonly, the lateral band of the plantar fascia during foot inversion.

Zone 2 “Jones fractures”

These occur at the metaphysis-diaphysis junction and extend into the fourth-fifth intermetatarsal facet. They result from forced forefoot adduction while the hindfoot is in plantar flexion.

Zone 3 “Diaphyseal stress fractures”

These are proximal diaphyseal fractures located distal to the articulation between the fourth and fifth metatarsal bases. They can be caused by acute excessive loading of the region or by chronic overloading, as seen in stress fractures.

Zone 2 and Zone 3 fractures are susceptible to delayed healing and non-union. Treatment strategies for these fractures depend on the patient’s activity level and the healing progress.

Recent studies have shown low interrater reliability for the 3-zone classification due to inconsistent definitions of Jones fractures among surgeons and difficulty in distinguishing between zone 2 and zone 3 injuries.^[14,15] This inconsistency may result in heterogeneous patient populations in clinical studies. Consequently, some have recommended abandoning the Lawrence and Botte classification in favor of a 2-zone (metaphyseal/meta-diaphyseal) classification.^[14]

MECHANISM OF INJURY AND BIOMECHANICAL CONSIDERATIONS

Zone 1 (tuberosity fractures)

Tuberosity fractures are the most common type of fracture. These avulsion-type fractures occur during forced inversion of the hindfoot with the forefoot in plantar flexion.^[9] Typically, these injuries happen when the foot inverts while running on uneven surfaces or landing awkwardly from a jump. Initially, the consensus was that the forceful contraction of the peroneus brevis tendon was the primary cause of tuberosity avulsion. However, subsequent studies indicated that the lateral band of the plantar fascia is the main contributor.^[7,9]

Zone 2 and zone 3

Athletes can sustain this injury during sudden, forceful changes in direction while the heel is off the ground. Landing in an inverted position can also increase stress on the metatarsals, potentially leading to fractures.^[16]

Stress fractures, on the other hand, are caused by repetitive overloading, which causes microfractures to occur at a rate that exceeds their repair ability. Various sports maneuvers have been analyzed to determine which ones apply the most stress on the fifth metatarsal. Acceleration maneuvers exert the highest bending moments on the fifth metatarsal, making them more likely to be associated with stress fractures along the shaft.^[17] In addition, plantar force at the lateral forefoot and lateral toes (2–5) peaks during two football movements: kicking and curved running.^[18]

Several risk factors are associated with proximal fifth metatarsal fractures due to the increased loading on the lateral column of the foot. Hindfoot varus, midfoot supination, and metatarsus adductus have been observed in patients who sustained fifth metatarsal fractures.^[19] O’Malley *et al.* noted an increased risk of refracture in National Basketball Association players with a higher metatarsus adductus angle.^[20] In addition, a high body mass index has been linked to an increased risk of zone 3 fractures attributed to the biomechanical and metabolic effects of excessive adipose tissue.^[21]

CLINICAL PRESENTATION

Patients typically present with pain, swelling, and bruising on the lateral aspect of the foot following an inversion injury. This presentation may resemble an ankle sprain; therefore, a careful examination using the Ottawa ankle rules is essential for accurate diagnosis. The presence of midfoot and hindfoot deformities should also be noted. A detailed medical history can help distinguish between acute fractures and stress fractures, with the latter often characterized by pain persisting for several weeks before the acute event and sometimes an increase in exercise intensity. In addition, clinicians should review the patient’s medical history, particularly if a stress fracture is suspected, including any history of vitamin D

deficiencies, endocrine disorders, osteoporosis, or metabolic bone disorders.^[1]

INVESTIGATIONS

Plain radiographs are the initial imaging modality of choice when a fracture is suspected. Anteroposterior (AP), lateral, and oblique views are required. Ankle radiographs can help visualize tuberosity fractures that are not visible on foot radiographs. Stress fractures may not be apparent in the early stages. Magnetic resonance imaging is usually the preferred investigation tool, although technetium bone scans can also be useful. Computed tomography scans are often used in cases of delayed union and non-union.

A thorough understanding of the anatomy is crucial when interpreting imaging of the fifth metatarsal base. Tuberosity fractures should not be confused with growth plates or accessory bones. It is important to note that the epiphyseal line runs parallel to the diaphysis and does not involve the joint, whereas a fracture line is perpendicular to the diaphyseal axis and usually involves the cuboid-metatarsal joint. Small accessory bones such as the os peroneum and os vesalianum pedis (OVP) could be observed in proximity to the base of the fifth metatarsal. OVP is a rare accessory bone that can be mistaken for a non-united tuberosity fracture [Figure 1]. X-rays of both feet are crucial for diagnosing OVP since it is typically bilateral.^[22]

Finally, a metabolic and endocrinal workup may be necessary, including screening for vitamin D and calcium levels, particularly in cases with stress fractures.

MANAGEMENT

Treatment options depend on the fracture location, the presence of radiographic union, and the patient's medical fitness and activity level.

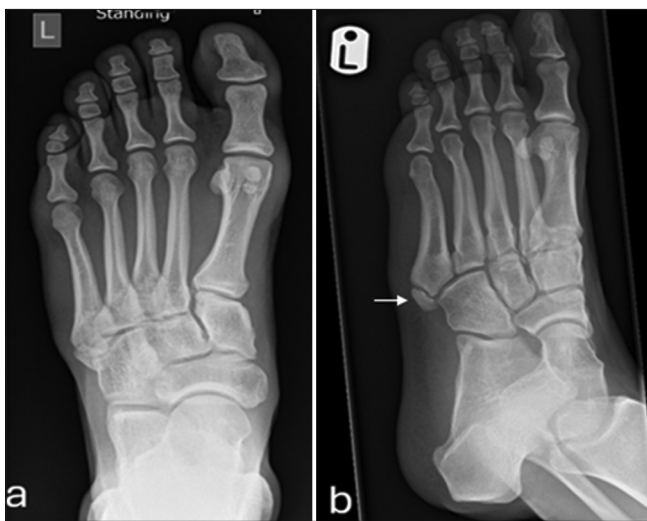

Figure 1: A 26-year-old footballer presented with foot pain after an injury. (a) Anteroposterior and (b) oblique radiographs showing os vesalianum pedis (white arrow).

Zone 1 (tuberosity fracture)

Non-displaced tuberosity avulsion fractures are typically treated non-operatively with high success rates for union.^[23] These patients generally require symptomatic treatment, although various forms of support, such as walking boots, hard-sole shoes, and cast immobilization, have been used. Few studies have compared early functional conservative management with immobilization. Most results showed that functional treatments provided better functional outcomes and earlier return to work compared to short leg cast treatment, with no differences in fracture union or re-fracture rates.^[24,25]

The treatment for displaced tuberosity fractures remains controversial. Some authors recommend surgical fixation for fractures with more than 2 mm displacement or involvement of more than 30% of the cuboid-metatarsal articulation even though this is not based on scientific evidence. Comparisons between operative and non-operative treatment of displaced tuberosity fractures show no statistical difference in clinical and radiological outcomes.^[26]

The treatment for non-united tuberosity fractures that have failed conservative management depends on the patient's demands, symptoms, and fracture size. Surgical treatment is usually not required for asymptomatic fibrous union.^[27] In symptomatic patients, surgery will depend on the size of the fragment. Small avulsion injuries that are not amenable to fixation can be treated with excision with or without reattachment of the peroneus brevis tendon.^[28] Larger fragments tend to be fixed. Several fixation methods can be used for tuberosity fractures, with the most common being IM screws, tension band wires, and ulnar hook plates [Figure 2]. Biomechanical studies indicate that cancellous screws are more stable than tension band wires,^[29] while hook plates are biomechanically superior to headless compression screws.^[30]

A recent systematic review of the different treatment modalities of base of the fifth metatarsal bone fracture concluded that early functional therapy is recommended for zone 1 fractures, including the displaced, intra-articular, and comminuted ones.^[31]

Zone 2 (Jones fracture)

Treatment should be tailored to the patient's needs and expectations. However, there has been an ongoing controversy among surgeons regarding the optimal treatment for zone 2 fractures. Some advocate for non-operative management due to favorable outcomes,^[6,32] while others support surgical intervention, particularly for high-demand patients.^[4,5,33,34] A major reason for these different opinions is the inconsistent use of the term "Jones fracture" to refer to both zone 2 and zone 3 fractures, with many studies grouping them together and leading to inaccurate results.

Conservative management typically involves non-weight-bearing for 6–8 weeks.^[12] However, recent studies have shown

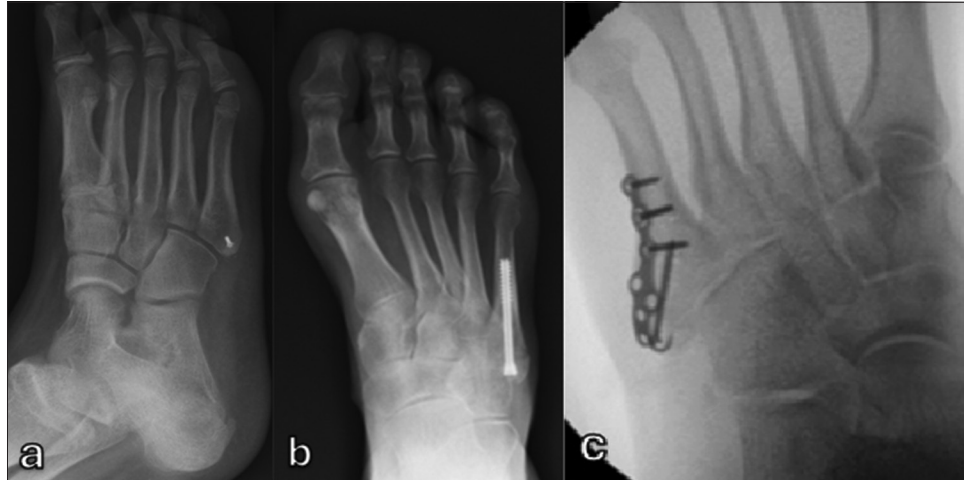


Figure 2: Radiographs showing fixation methods for tuberosity avulsion fracture. (a) Fragment excision and re-attachment of peroneus brevis tendon using bone anchor. (b) Intramedullary screw fixation. (c) Fixation with hook plate.

favorable outcomes with functional treatment that allows for early weight-bearing and free motion. A recent retrospective study of 834 proximal fifth metatarsal fractures showed no difference in time to union between weight-bearing as tolerated and non-weight-bearing treatment strategies for all fracture zones.^[35]

Surgical treatment is recommended for high-level athletes due to its association with a significantly earlier return to play and lower rates of non-union. A recent meta-analysis of 22 studies involving athletes with acute fractures at the intermetatarsal area or proximal diaphysis found that those who underwent surgical fixation achieved a quicker time to union with a higher union rate (97.3%, compared with 71.4% for those managed conservatively), and a shorter time to return to play than did those who underwent non-operative management (9.6 weeks vs. 13.1 weeks).^[33] Comparable findings have been reported in other studies.^[4]

Several methods of fixation have been described for zone 2 fractures, with IM screw fixation being the most common. IM screw fixation combined with aggressive rehabilitation protocols has become popular for treating Jones fractures in professional athletes. In a case series, Watson *et al.* treated 23 athletes with Jones fractures using IM screws, followed by aggressive rehabilitation. They found that all athletes returned to play within an average of 3.6 weeks (maximum of 6 weeks), which suggests that the return to play was not dependent on the radiological union. No cases of non-union were reported, although one athlete experienced a refracture after screw removal.^[36] Certain technical considerations must be considered when fixing these fractures to prevent complications. Properly sized screw is essential to provide adequate strength and prevent refracture and screw breakage. Some studies advised that IM screws should be at least 4.5 mm in diameter with smaller screw diameters associated

with failure, delayed or non-union.^[37,38] However, overly large IM screws may cause stress shielding, further fracture, and ultimately delayed or non-union. In addition, solid screws have demonstrated greater fatigue resistance compared to cannulated screws.^[39] Headless compression screws provide more stiffness at the fracture site than conventional partially threaded screws but are challenging to remove if necessary.^[40] Proper screw length is crucial due to the curvature of the fifth metatarsal. Excessive screw length can breach the diaphyseal cortex, causing fracture distraction and gapping. Therefore, the screw length should be <66% of the length of the fifth metatarsal.^[41]

Plantar plate fixation is an alternative method for treating fifth metatarsal stress fractures. This method is thought to offer improved rotational resistance at the fracture site and functions as a tension band to counteract the tensile stress on the plantar lateral side of the fracture. Good outcomes have been reported with the use of plantar plates, particularly in athletic populations, though complications such as refractures and hardware prominence have been noted.^[42]

Other fixation methods include tension band wiring, either through the conventional or modified technique, which uses two cortical screws.^[43] The fifth metatarsal, extra-portal, rigid, innovative technique combines an IM cannulated medium-diameter screw with a high-resistance suture, such as FiberWire®, to enhance biomechanical stability. This approach may be an effective option to improve fixation strength when the use of large-diameter screws is restricted.^[44] Recently, Jones-specific implants have been introduced to provide more customized fixation for proximal fifth metatarsal fractures, but further studies are needed to demonstrate their effectiveness.^[45]

In cases of refracture or delayed/non-unions, management typically includes fracture site debridement, the use of bone

Table 1: Summary of the characteristics and treatment methods for each zone of injury.

Zone of injury	Description	Mechanism of injury	Union rates	Treatment methods
Zone 1	Tuberosity avulsion fracture	Forceful contraction of the peroneus brevis or lateral band of the plantar fascia during foot inversion	Non-union is uncommon	<ul style="list-style-type: none"> • Functional treatment: For most cases • Surgical treatment: For severely displaced fractures and symptomatic non-union. (Excision, IM screw, hook plate, tension band wire)
Zone 2 (Jones fracture)	<ul style="list-style-type: none"> - Fracture at the metaphyseal-diaphyseal junction - Involves the fourth and fifth metatarsal articulation 	Forced forefoot adduction while the hindfoot is in plantar flexion	Increased risk of delayed and non-union	<ul style="list-style-type: none"> • Depend on patient's needs • Functional treatment: For low-demand patients • Surgical treatment: For high-demand patients (IM screw, plantar plate, tension band wire)
Zone 3	<ul style="list-style-type: none"> - Proximal diaphyseal fracture - Distal to the fourth and fifth metatarsal articulation 	Repetitive overloading	Increased risk of delayed and non-union	<ul style="list-style-type: none"> • Conservative treatment: For low-demand patients (Cast immobilization, ESWT) • Surgical treatment: For high-demand patients (IM screw, plantar plate with or without bone grafting)

IM: Intramedullary, ESWT: Extracorporeal shock wave therapy

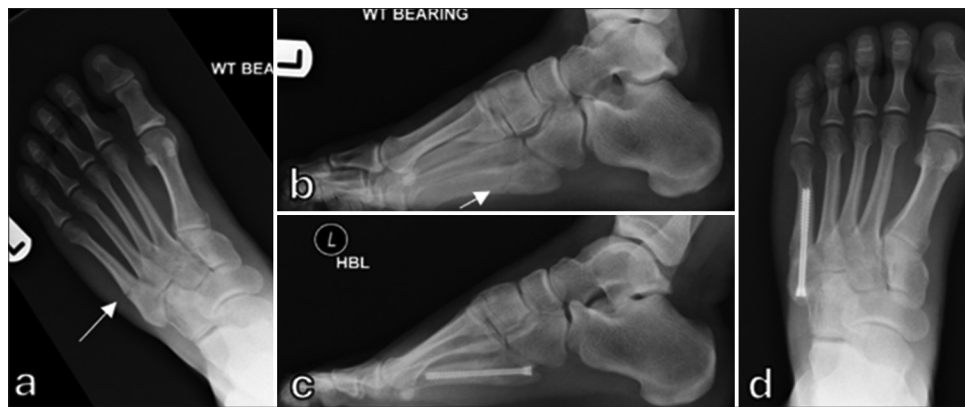

Figure 3: (a) Anteroposterior and (b) lateral radiographs of a 19-year-old professional footballer showing Jones-type fracture (white arrows). (c) Anteroposterior and (d) lateral radiographs 10 weeks later showing union following intramedullary screw fixation.

grafting or bone mineral proteins, and stabilization with an IM screw.^[46] However, Grant *et al.* found no need to prepare the fracture site in their case series. They demonstrated that union was achieved within 3 months in all cases of non-union treated with percutaneous screw fixation without fracture site debridement.^[47] For revision of previous screw fixation, a larger diameter screw and re-reaming of the medullary canal are usually required.

Extracorporeal shock wave therapy (ESWT) has demonstrated positive outcomes in treating delayed and non-union fractures despite most studies having small sample sizes. Similarly, a recent randomized controlled study found that ESWT and surgical treatment were equally effective in reducing pain and achieving bone healing in soccer players with proximal fifth metatarsal stress fractures.^[48]

Zone 3 (proximal diaphyseal stress fracture)

These fractures are more prone to delayed union, non-union, and refracture. Treatment is similar to that for zone 2 fractures. In acute cases, conservative treatment with cast immobilization and non-weight-bearing can be considered for non-athletic individuals. However, for athletes, early surgical fixation with an IM screw is recommended to achieve a shorter union time and a quicker return to sports.^[49] A summary of the characteristics and treatment methods for each zone of injury is shown in Table 1.

Author's experience

Treatment is tailored to the fracture configuration and patient demands. We recommend functional management for tuberosity avulsion fractures, allowing patients to weight bear as tolerated. For non-operative treatment of Zone 2 fractures,

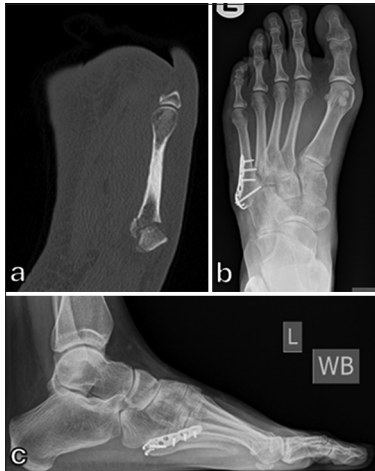

Figure 4: 30-year-old female runner 8 weeks after injury. (a) Computed tomography scan showing comminuted tuberosity fracture. (b) Anteroposterior and (c) lateral radiographs following fixation with a hook plate.

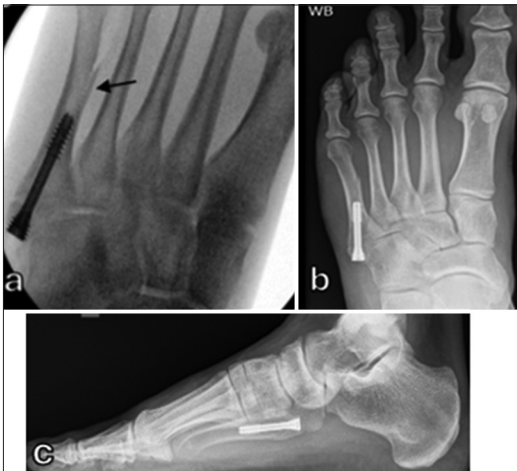

Figure 5: (a) Intraoperative radiograph showing iatrogenic fracture (black arrow) in the fifth metatarsal shaft following fixation with intramedullary screw. (b) Anteroposterior and (c) lateral radiographs showing both fractures united 3 months after surgery.

patients can weight bear in a walker boot for 6–12 weeks. If there is no evidence of clinical and radiographic union by 12 weeks, surgical fixation is recommended. In high-demand or athletic patients, surgical fixation with IM screw may be considered the first line of treatment, following a discussion of treatment options with the patient [Figure 3]. For Zone 3 fractures, we opt for percutaneous fixation without fracture site debridement. Hook plates are reserved for comminuted tuberosity fractures [Figure 4].

COMPLICATIONS

General complications of proximal fifth metatarsal fractures include non-union, delayed union, refracture, and persistent pain.^[23,37] While tuberosity fractures generally exhibit high union rates,^[23] the rates of delayed and non-union for conservatively treated acute Jones fractures range from 7% to 67%.^[12,37] In addition, ongoing pain has been observed in 25–33% of patients 1 year after sustaining a proximal fifth metatarsal fracture.^[50]

Complications specific to surgical fixation include refracture, malunion, delayed union, non-union, wound infection, sural nerve injury, hardware irritation/failure, and iatrogenic fracture^[11,37] [Figure 5].

CONCLUSION

Fifth metatarsal fractures, particularly those involving the proximal segment, present significant challenges due to their unique anatomical and biomechanical characteristics.

Management strategies vary based on the type of fracture, patient activity level, and individual patient needs. For tuberosity fractures (Zone 1), functional therapy has been shown to be particularly effective, allowing early mobilization without compromising healing. In contrast, the management of Jones fractures (Zone 2) remains controversial. High-demand athletes are likely to benefit from surgical intervention, which facilitates a quicker return to activity and lower rates of non-union. The same applies to Zone 3 fractures.

Future research should aim to refine classification systems to enhance diagnostic accuracy and treatment outcomes. In addition, more randomized controlled trials are necessary to compare conservative and surgical treatments across various patient populations and to evaluate different fixation techniques.

Ethical approval

Institutional Review Board approval is not required.

Declaration of patient consent

Patient's consent is not required as there are no patients in this study.

Financial support and sponsorship

Nil.

Conflicts of interest

There are no conflicts of interest.

Use of artificial intelligence (AI)-assisted technology for manuscript preparation

The authors confirm that there was no use of artificial intelligence (AI)-assisted technology for assisting in the writing or editing of the manuscript and no images were manipulated using AI.

REFERENCES

1. Kane JM, Sandrowski K, Saffel H, Albanese A, Raikin SM, Pedowitz DI. The epidemiology of fifth metatarsal fracture. *Foot Ankle Spec* 2015;8:354-9.
2. Smith JW, Arnoczky SP, Hersh A. The intraosseous blood supply of the fifth metatarsal: Implications for proximal fracture healing. *Foot Ankle*

- 1992;13:143-52.
3. Jones R. I. Fracture of the base of the fifth metatarsal bone by indirect violence. *Ann Surg* 1902;35:697-700.2.
 4. Roche AJ, Calder JD. Treatment and return to sport following a Jones fracture of the fifth metatarsal: A systematic review. *Knee Surg Sports Traumatol Arthrosc* 2013;21:1307-15.
 5. Goodloe JB, Cregar WM, Caughman A, Bailey EP, Barfield WR, Gross CE. Surgical management of proximal fifth metatarsal fractures in elite athletes: A systematic review. *Orthop J Sports Med* 2021;9. Available from: <http://dx.doi.org/10.1177/23259671211037647> [Last accessed on 2024 Oct 15].
 6. Kim C, Shin DY, Kim J. Is surgical treatment necessary for the treatment of a Jones fracture?: A retrospective study. *Clin Orthop Surg* 2024;16:335-41.
 7. Richli WR, Rosenthal DI. Avulsion fracture of the fifth metatarsal: Experimental study of pathomechanics. *AJR Am J Roentgenol* 1984;143:889-91.
 8. Kaneko F, Edama M, Ikezu M, Matsuzawa K, Hirabayashi R, Kageyama I. Anatomic characteristics of tissues attached to the fifth metatarsal bone. *Orthop J Sports Med* 2020;8. Available from: <http://dx.doi.org/10.1177/2325967120947725> [Last accessed on 2024 Oct 15].
 9. DeVries JG, Taefi E, Bussewitz BW, Hyer CF, Lee TH. The fifth metatarsal base: Anatomic evaluation regarding fracture mechanism and treatment algorithms. *J Foot Ankle Surg* 2015;54:94-8.
 10. Morris PM, Francois AG, Marcus RE, Farrow LD. The effect of peroneus brevis tendon anatomy on the stability of fractures at the fifth metatarsal base. *Foot Ankle Int* 2015;36:579-84.
 11. Fansa AM, Smyth NA, Murawski CD, Kennedy JG. The lateral dorsal cutaneous branch of the sural nerve: Clinical importance of the surgical approach to proximal fifth metatarsal fracture fixation. *Am J Sports Med* 2012;40:1895-8.
 12. Torg JS, Balduini FC, Zelko RR, Pavlov H, Peff TC, Das M. Fractures of the base of the fifth metatarsal distal to the tuberosity. Classification and guidelines for non-surgical and surgical management. *J Bone Joint Surg Am* 1984;66:209-14.
 13. Lawrence SJ, Botte MJ. Jones' fractures and related fractures of the proximal fifth metatarsal. *Foot Ankle* 1993;14:358-65.
 14. Michalski MP, Ingall EM, Kwon JY, Chiodo CP. Reliability of fifth metatarsal base fracture classifications and current management. *Foot Ankle Int* 2022;43:1034-40.
 15. Noori N, Abousayed M, Guyton GP, Coleman MM. What is the interrater and intrarater reliability of the Lawrence and botte classification system of fifth metatarsal base fractures? *Clin Orthop Relat Res* 2022;480:1305-9.
 16. Hunt KJ, Goeb Y, Bartolomei J. Dynamic loading assessment at the fifth metatarsal in elite athletes with a history of Jones fracture. *Clin J Sport Med* 2021;31:e321-6.
 17. Orendurff MS, Rohr ES, Segal AD, Medley JW, Green JR 3rd, Kadel NJ. Biomechanical analysis of stresses to the fifth metatarsal bone during sports maneuvers: Implications for fifth metatarsal fractures. *Phys Sportsmed* 2009;37:87-92.
 18. Thomson A, Akenhead R, Whiteley R, D'Hooghe P, Van Alsenoy K, Bleakley C. Fifth metatarsal stress fracture in elite male football players: An on-field analysis of plantar loading. *BMJ Open Sport Exerc Med* 2018;4:e000377.
 19. Fuchs D, Kane J, Brodsky J, Royer C, Zide J, Reddy V, *et al*. The Cavovarus foot and its association with fractures of the fifth metatarsal. *Foot Ankle Orthop* 2017;2. Available from: <http://dx.doi.org/10.1177/2473011417s000173> [Last accessed on 2024 Oct 15].
 20. O'Malley M, DeSandis B, Allen A, Levitsky M, O'Malley Q, Williams R. Operative treatment of fifth metatarsal Jones fractures (Zones II and III) in the NBA. *Foot Ankle Int* 2016;37:488-500.
 21. Pugliese M, De Meo D, Sinno E, Pambianco V, Cavallo AU, Persiani P, *et al*. Can body mass index influence the fracture zone in the fifth metatarsal base? A retrospective review. *J Foot Ankle Res* 2020;13:9.
 22. Kalbouneh H, Alajoulin O, Shawaqfeh J, Abu-Hassan D, Al-Juboori S, Jaber S, *et al*. The anatomical variations of the lateral sesamoid bones of the foot: A retrospective radiographic analysis. *Folia Morphol (Warsz)* 2022;81:983-90.
 23. Rikken QG, Dahmen J, Hagemeyer NC, Sierevelt IN, Kerkhoffs GM, DiGiovanni CW. Adequate union rates for the treatment of acute proximal fifth metatarsal fractures. *Knee Surg Sports Traumatol Arthrosc* 2021;29:1284-93.
 24. Bayram S, Kendirci AŞ, Kiral D, Şahinkaya T, Ekinci M, Batbay SG, *et al*. Isokinetic strength comparison of tuberosity fractures of the proximal fifth metatarsal treated with elastic bandage vs cast. *Foot Ankle Int* 2020;41:674-82.
 25. Smith TO, Clark A, Hing CB. Interventions for treating proximal fifth metatarsal fractures in adults: A meta-analysis of the current evidence-base. *Foot Ankle Surg* 2011;17:300-7.
 26. Lee TH, Lee JH, Chay SW, Jang KS, Kim HJ. Comparison of clinical and radiologic outcomes between non-operative and operative treatment in 5th metatarsal base fractures (Zone 1). *Injury* 2016;47:1789-93.
 27. Solan M, Davies M. Nonunion of fifth metatarsal fractures. *Foot Ankle Clin* 2014;19:499-519.
 28. Ritchie JD, Shaver JC, Anderson RB, Lawrence SJ, Mair SD. Excision of symptomatic nonunions of proximal fifth metatarsal avulsion fractures in elite athletes. *Am J Sports Med* 2011;39:2466-9.
 29. Husain ZS, DeFronzo DJ. Relative stability of tension band versus two-cortex screw fixation for treating fifth metatarsal base avulsion fractures. *J Foot Ankle Surg* 2000;39:89-95.
 30. Bean BA, Smyth NA, Abbasi P, Parks BG, Hembree WC. Biomechanical comparison of hook plate vs headless compression screw fixation of large fifth metatarsal base avulsion fractures. *Foot Ankle Int* 2021;42:89-95.
 31. Herterich V, Baumbach SF, Kaiser A, Böcker W, Polzer H. Fifth metatarsal fracture—a systematic review of the treatment of fractures of the base of the fifth metatarsal bone. *Dtsch Arztebl Int* 2021;118:587-94.
 32. Baumbach SF, Urresti-Gundlach M, Böcker W, Vosseller JT, Polzer H. Results of functional treatment of epi-metaphyseal fractures of the base of the fifth metatarsal. *Foot Ankle Int* 2020;41:666-73.
 33. Attia AK, Taha T, Kong G, Alhammoud A, Mahmoud K, Myerson M. Return to play and fracture union after the surgical management of Jones fractures in athletes: A systematic review and meta-analysis. *Am J Sports Med* 2021;49:3422-36.
 34. Yates J, Feeley I, Sasikumar S, Rattan G, Hannigan A, Sheehan E. Jones fracture of the fifth metatarsal: Is operative intervention justified? A systematic review of the literature and meta-analysis of results. *Foot (Edinb)* 2015;25:251-7.
 35. Pettersen PM, Radojicic N, Grün W, Andresen TKM, Molund M. Proximal fifth metatarsal fractures: A retrospective study of 834 fractures with a minimum follow-up of 5 years. *Foot Ankle Int* 2022;43:602-8.
 36. Watson S, Trammell A, Tanner S, Martin S, Bowman L. Early return to play after intramedullary screw fixation of acute Jones fractures in collegiate athletes: 22-Year experience. *Orthop J Sports Med* 2020;8:2325967120912423.
 37. Granata JD, Berlet GC, Philbin TM, Jones G, Kaeding CC, Peterson KS. Failed surgical management of acute proximal fifth metatarsal (Jones) fractures: A retrospective case series and literature review. *Foot Ankle Spec* 2015;8:454-9.
 38. Scott RT, Hyer CF, DeMill SL. Screw fixation diameter for fifth metatarsal Jones fracture: A cadaveric study. *J Foot Ankle Surg* 2015;54:227-9.
 39. Reese K, Litsky A, Kaeding C, Pedroza A, Shah N. Cannulated screw fixation of Jones fractures: A clinical and biomechanical study. *Am J Sports Med* 2004;32:1736-42.
 40. Lam K, Bui R, Morris R, Panchbhavi V. Biomechanical analysis of conventional partially threaded screws versus headless compression screws in proximal fifth metatarsal (Jones) fracture fixation. *Foot Ankle Spec* 2021;14:509-14.
 41. Cates NK, Gulati AR, Tenley JD, O'Hara NN, Wynes J, Brandão RA. Screw length associated with fracture gapping of fifth metatarsal base fracture with intramedullary screw fixation: A cadaveric study. *J Foot Ankle Surg* 2022;61:986-90.
 42. Young KW, Kim JS, Lee HS, Jegal H, Park YU, Lee KT. Operative results of plantar plating for fifth metatarsal stress fracture. *Foot Ankle Int* 2020;41:419-27.
 43. Lee KT, Park YU, Young KW, Kim JS, Kim JB. Surgical results of 5th metatarsal stress fracture using modified tension band wiring. *Knee Surg Sports Traumatol Arthrosc* 2011;19:853-7.
 44. Su KC, Yen YC, Wang CH, Wang YL, Wang SP. Biomechanical comparisons of F.E.R.I. techniques with different type of intramedullary screws fixation for Jones fractures. *Front Bioeng Biotechnol* 2024;12:1389127.
 45. Chopra A, Anastasio AT, Fletcher AN, Tabarestani TQ, Sharma A, Parekh SG. Short-term outcomes of Jones-specific implant versus intramedullary screw and plate fixation for proximal fifth metatarsal fractures. *J Foot Ankle Surg* 2023;62:862-7.

46. Hunt KJ, Anderson RB. Treatment of Jones fracture nonunions and refractures in the elite athlete: Outcomes of intramedullary screw fixation with bone grafting. *Am J Sports Med* 2011;39:1948-54.
47. Grant MJ, Molloy AP, Mason LW. The use of percutaneous screw fixation without fracture site preparation in the treatment of fifth metatarsal base nonunion. *J Foot Ankle Surg* 2020;59:753-7.
48. Ramon S, Lucenteforte G, Alentorn-Geli E, Steinbacher G, Unzurrunzaga R, Álvarez-Díaz P, *et al*. Shockwave treatment vs surgery for proximal fifth metatarsal stress fractures in soccer players: A pilot study. *Foot Ankle Int* 2023;44:1256-65.
49. Cheung CN, Lui TH. Proximal fifth metatarsal fractures: Anatomy, classification, treatment and complications. *Arch Trauma Res* 2016;5:e33298.
50. Bigsby E, Halliday R, Middleton RG, Case R, Harries W. Functional outcome of fifth metatarsal fractures. *Injury* 2014;45:2009-12.

How to cite this article: Eldessouky A, Bhatia M. Fifth metatarsal fractures: Review of the current concepts. *J Arthrosc Surg Sports Med*. doi: 10.25259/JASSM_34_2024