

Original Article

The prevalence of synovitis during hip arthroscopy for labral tears – An observational study

Ahmed Saad¹, Alistair IW Mayne¹, Karthikeyan P. Iyengar², Peter Wall¹, Angelos Politis¹, C. E. Bache¹, Callum McBryde¹, Rajesh Botchu³

¹Department of Young Adult Hip Surgery, Royal Orthopedic Hospital, Birmingham, West Midlands, ²Department of Orthopedics, Mersey and West Lancashire Teaching Hospitals NHS Trust, Southport and Ormskirk Hospital, Southport, ³Department of Musculoskeletal Radiology, Royal Orthopedic Hospital, Birmingham, United Kingdom.

ABSTRACT

Objectives: Hip pain, secondary to labral tears (LT), can significantly impact the quality of life in the young adult population. LTs can be an incidental finding or can arise from underlying pathology, most commonly from femoroacetabular impingement (FAI). The cause of hip pain in young adults can represent a diagnostic challenge to clinicians. Magnetic resonance imaging (MRI)/magnetic resonance arthrography may be inconclusive in some cases. Therefore, diagnostic hip arthroscopy may be performed to provide a definitive diagnosis and to address intra-articular pathology. During hip arthroscopy, synovitis is often an initial finding. Synovitis can have multiple causes or can also be idiopathic. The aim of this study was to determine the incidence of synovitis detected during hip arthroscopy in patients with an MRI-confirmed LT.

Materials and Methods: We conducted a prospective review of 50 consecutive patients undergoing hip arthroscopy who had a confirmed LT on MRI. We recorded the presence or absence of synovitis during the initial insertion of the arthroscope. In addition, we recorded demographic data and the grade of LT identified.

Results: During hip arthroscopy, 31 patients had synovitis present, while 19 did not have synovitis. No significant difference was identified when comparing Visual Analog Score and EQ5D scores between both cohorts.

Conclusion: Our study found that synovitis is a common finding during hip arthroscopy for FAI syndrome, with 62% of patients with an MRI diagnosis of LT associated with FAI having global hip synovitis present at the time of surgery.

Keywords: Hip arthroscopy, Labral tear, Magnetic resonance arthrography, Magnetic resonance imaging, Synovitis

INTRODUCTION

Hip pain can significantly affect the quality of life in young adults.^[1] The underlying etiology may include both intra-articular and extra-articular causes, necessitating assessment by orthopedic clinicians with specialized knowledge to ensure that treatable conditions are identified and managed. Labral tears (LTs) are commonly observed during evaluations of young adults presenting with hip pain. These tears may be incidental findings or result from underlying pathologies, most notably femoroacetabular impingement (FAI).^[2] Other frequent causes include acetabular dysplasia, rotational malalignment, femoral head deformity, or a combination of these factors.^[3-5]

Diagnosing the cause of hip pain in young adults can be challenging, with studies indicating that it often takes over

2 years to reach a definitive diagnosis.^[6-8] While magnetic resonance imaging (MRI) and magnetic resonance arthrography (MRA) are crucial for initial imaging, they can yield false positives for LTs or produce inconclusive results.^[6,9,10] In cases with a high suspicion of intra-articular pathology, hip arthroscopy may be performed to provide a definitive diagnosis and address any intra-articular issues.

During hip arthroscopy, synovitis is frequently observed upon initial insertion of the arthroscope, manifesting as inflammation of the synovial membrane lining the hip joint capsule [Figures 1 and 2]. This inflammation can be localized or widespread, with potential causes including hip osteoarthritis, inflammatory conditions, trauma, FAI, or LTs.^[11]

To date, no studies have investigated the prevalence of synovitis during hip arthroscopy, its potential clinical

*Corresponding author: Rajesh Botchu, Department of Musculoskeletal Radiology, Royal Orthopedic Hospital, Birmingham, United Kingdom. drrajeshb@gmail.com

Received: 21 July 2024 Accepted: 09 October 2024 Epub Ahead of Print: 05 November 2024 Published: 01 February 2025 DOI: 10.25259/JASSM_33_2024

This is an open-access article distributed under the terms of the Creative Commons Attribution-Non Commercial-Share Alike 4.0 License, which allows others to remix, transform, and build upon the work non-commercially, as long as the author is credited and the new creations are licensed under the identical terms. ©2025 Published by Scientific Scholar on behalf of Journal of Arthroscopic Surgery and Sports Medicine

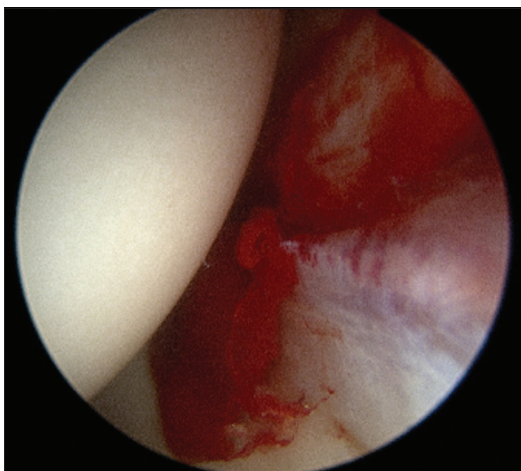


Figure 1: Hip synovitis.

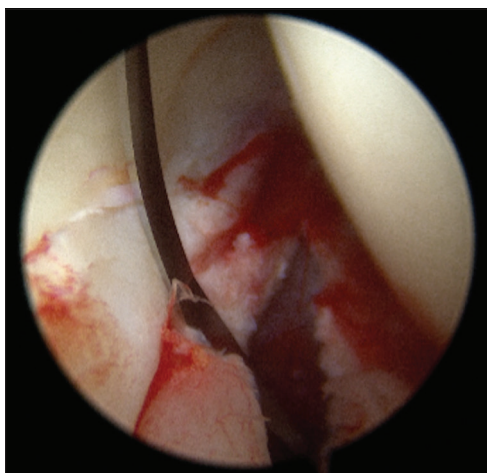


Figure 2: Hip synovitis during the creation of capsulotomy.

implications, or its correlation with the presence of LTs. This study aims to elucidate the incidence of synovitis detected during hip arthroscopy in patients with MRI-confirmed LTs.

MATERIALS AND METHODS

We prospectively collected data on 50 consecutive patients who underwent a hip arthroscopy for an MRI-confirmed LT between September 2022 and April 2023 and recorded the presence or absence of global hip synovitis during the initial insertion of the hip scope. In addition, we recorded demographic data, including age and gender, and the grade of LT identified, based on the BARC classification:^[12] (1) labral fraying, (2) LT suitable for repair, and (3) degenerate labrum. To assess potential clinical implications, we collected Visual Analog Scores (VAS pain score) and EQ-5D scores for each patient pre-operatively and performed a comparative analysis between those with and without synovitis. All data

Table 1: The total number of patients with or without synovitis on initial hip arthroscopy.

Synovitis on hip arthroscopy	<i>n</i>
Yes	31
No	19

Table 2: The total number of patients with synovitis present versus the degree of labral tear.

Grade of labrum in patients with synovitis	<i>n</i>
Grade I	0
Grade II	27
Grade III	4

Table 3: The total number of patients with no synovitis present versus the degree of labral tear.

Grade of labrum in patients with no synovitis	<i>n</i>
No tear	0
Grade I	1
Grade II	13
Grade III	5

collected by the same trained surgeon (AM) for consistency and reliability were input into Microsoft Excel for subsequent analysis.

Data analysis involved simple statistical methods using GraphPad software, including the calculation of descriptive statistics such as means and percentages for data summary. To evaluate the association between VAS and EQ5D pain scores and synovitis, we conducted an analysis of variance (ANOVA) test with a $P = 0.05$ considered statistically significant. *Post hoc* analysis using the Tukey test was then performed to strengthen our statistical findings.

Ethical committee approval was not required as it is a retrospective study of anonymous data.

RESULTS

The study cohort of 50 patients included 31 females and 19 males, with a mean age of 33 years (range: 20–54). During hip arthroscopy, 62% ($n = 31$) of patients were noted to have global hip synovitis, while 38% ($n = 19$) did not [Tables 1-3]. Among the 31 patients with synovitis, 17 were female and 14 were male. Utilizing the BARC classification for LTs, we observed that the majority of patients (87%, $n = 27$) had a grade II tear, whereas only 13% ($n = 4$) had a grade III tear. None of the patients exhibited grade I pathology. Out of this cohort of patients with synovitis, 26 patients had recorded VAS and EQ5D scores, while data were unavailable for the remaining 5 patients. The average VAS score for patients with synovitis was 73.7 (ranging from 40 to 100), and the mean EQ5D score was 0.6 (ranging from 0.32 to 0.8).

Among the total of 19 patients without synovitis, 15 were female and 4 were male. Of these patients, the majority (68%, $n = 13$) had a grade II LT, while 26% had a grade III tear, and only one patient had grade I labral pathology. Of the 19 patients, 16 patients had recorded VAS and EQ5D scores, while 3 patients had no available scores present. The average VAS score for patients without synovitis was 68.3 (with a range of 20–93) and a mean EQ5D score of 0.5 (ranging from 0.04 to 0.84).

Conducting an ANOVA analysis to compare VAS and EQ5D scores between patients with synovitis and those without, we found no significant difference, with a $P = 0.37$ for VAS score comparison and 0.15 for EQ5D. These findings were further supported by a *post hoc* analysis using the Tukey test.

DISCUSSION

This study has demonstrated that the majority (62%) of patients undergoing hip arthroscopy with an MRI confirmed LT had significant synovitis within the hip joint. Despite this, although pathological LTs are thought to be a significant pain generator, the analysis of VAS and EQ5D scores revealed no significant difference between patients with synovitis and those without, indicating that the presence of synovitis may not directly impact pain severity and quality of life in patients with LTs.

The labrum is a triangular-shaped fibrocartilaginous structure that attaches to and surrounds almost the entirety of the acetabular rim, transitioning into the transverse acetabular ligament inferiorly.^[13,14] The anterior part of the labrum is wider and thinner, while the posterior labrum is thicker and has a sulcus formation, which can be mistaken for a pathological feature.^[13,14] The labrum plays an important role in hip joint stability by deepening the joint and maintaining the suction seal of the joint. The negative pressure created by this suction seal helps to maintain the synovial fluid, which lubricates and nourishes the joint and helps distribute contact forces across the articular surfaces.^[13,14]

The location of LT is an important consideration for treatment methods and often corresponds to the area of mechanical conflict between the femur and acetabulum. The most common and simple classification used is based on their location within the labrum, including anterior, posterior, and superolateral tears, of which the latter are the most common.^[15–20] Determining the underlying cause of LTs is essential for determining the most effective treatment approach.^[15–18] This can be challenging, especially when associated with subtle structural abnormalities.

Typically, the first imaging modality used in young adults presenting with anterior hip and groin pain is radiographic evaluation, which can reveal structural abnormalities within the joint, including osteoarthritis, dysplasia, and CAM morphology. However, further evaluation with MRI and/or MRA is often performed to further assess labral and

chondral lesions, as well as provide detailed information on the morphology of the acetabulum and proximal femur.^[21,22] Although MRI is a useful tool for diagnosing LTs, it has limited sensitivity, with reported rates of around 66%,^[23] and can underestimate the severity of labral pathology. Furthermore, recesses (such as the anterior sublabral recess) seen on MRI can often provide false-positive results, further complicating diagnosis on MRI.^[21–24] The current gold standard imaging technique for LTs is MRA.^[21] However, MRA is an invasive procedure with limitations to its sensitivity and specificity found to range from 60% to 100% and 44% to 100%,^[25,26] respectively, compared to diagnostic arthroscopy. Therefore, diagnostic hip arthroscopy may occasionally be used for further evaluation in cases where there is a high degree of clinical suspicion for intra-articular pathology.

Hip arthroscopy is considered the gold standard for the diagnosis and treatment of symptomatic LTs arising from FAI syndrome.^[27] Several studies have suggested that the key cause of pain induced by LT is secondary to synovial inflammation and that labral degeneration is positively correlated with it, especially in patients with FAI.^[28–31] The incidence of synovial inflammation in the presence of LT has not been described previously. Our study found that approximately 62% of patients with LTs also had significant hip synovitis.

Limitation

It is important to note the limitations of this study when interpreting the findings. The study only investigated the incidence of synovitis at hip arthroscopy in patients who had prior confirmed diagnosis of LT on MRI. We do not know the incidence of synovitis in asymptomatic patients as a comparison group, but it would be expected that this is less common. Although the study provides information on the incidence of synovitis in patients with MRI-confirmed LT, it does not establish a relationship between the two conditions. Further research is necessary to explore the relationship between synovitis and LTs.

CONCLUSION

Our study found that global hip synovitis is present in 62% of patients with an MRI-confirmed diagnosis of LT. If synovitis is present during hip arthroscopy, its presence can guide surgeons to carefully examine the labrum for a tear during hip arthroscopy, particularly in cases where LTs are not initially diagnosed on MRI. Our findings contribute to the evolving body of knowledge regarding hip arthroscopy.

Author contributions: AS, RB: Conception and design, or acquisition of data, or analysis and interpretation of data; AS, CM, RB: Design, or acquisition of data, or analysis and interpretation of data; SA, AM, KI, PW, AP, CB, CM, RB: Drafting the article or revising it critically for important intellectual content, and final approval of the version to be published.

Ethical approval: The Institutional Review Board approval is not required since it is a retrospective study of anonymous data.

Declaration of patient consent: Patient's consent is not required as there are no patients in this study.

Financial support and sponsorship: Nil.

Conflicts of interest: There are no conflicts of interest.

Use of artificial intelligence (AI)-assisted technology for manuscript preparation: The authors confirm that there was no use of artificial intelligence (AI)-assisted technology for assisting in the writing or editing of the manuscript and no images were manipulated using AI.

REFERENCES

1. Wenger DE, Kendall KR, Miner MR, Trousdale RT. Acetabular labral tears rarely occur in the absence of bony abnormalities. *Clin Orthop Relat Res* 2004;426:145-50.
2. Tanzer M, Noiseux N. Osseous abnormalities and early osteoarthritis: The role of hip impingement. *Clin Orthop Relat Res* 2004;429:170-7.
3. Kim K, Hwang D, Lee C, Kwon ST. Influence of femoroacetabular impingement on results of hip arthroscopy in patients with early osteoarthritis. *Clin Orthop Relat Res* 2007;456:128-32.
4. Larson CM, Giveans MR, Stone RM. Arthroscopic debridement versus refixation of the acetabular labrum associated with femoroacetabular impingement: Mean 3.5-year follow-up. *Am J Sports Med* 2012;40:1015-21.
5. Philippon M, Briggs K, Yen Y, Kuppersmith DA. Outcomes following hip arthroscopy for femoroacetabular impingement with associated chondrolabral dysfunction: Minimum two-year follow-up. *J Bone Joint Surg Br* 2009;91:16-23.
6. Lewis CL, Sahrman SA. Acetabular labral tears. *Phys Ther* 2006;86:110-21.
7. McCarthy JC, Busconi B. The role of hip arthroscopy in the diagnosis and of hip disease. *Orthopedics* 1995;18:753-6.
8. Farjo LA, Glick JM, Sampson TG. Hip arthroscopy for acetabular labral tears. *Arthroscopy* 1999;15:132-7.
9. Czerny C, Hofmann S, Neuhold A, Tschauner C, Engel A, Recht MP, *et al.* Lesions of the acetabular labrum: Accuracy of MR imaging and MR arthrography in detection and staging. *Radiology* 1996;200:225-30.
10. Hunt D, Clohisy J, Prather H. Acetabular tears of the hip in women. *Phys Med Rehabil Clin N Am* 2007;18:497-520.
11. Seidman AJ, Limaie F. Synovial fluid analysis. In: StatPearls. Treasure Island, FL: StatPearls Publishing; 2023. Available from: <https://www.ncbi.nlm.nih.gov/books/NBK537114> [Last accessed on 2022 May 08].
12. Elnahal WA, Azzopardi C, Strambi F, Nandra R, Botchu R, McBryde CW, *et al.* Can non-contrast 3T MRI scans predict the type of labral procedure in hip arthroscopy? *Eur J Orthop Surg Traumatol* 2023;33:1291-7.
13. Bharam S. Labral tears, extra-articular injuries, and hip arthroscopy in the athlete. *Clin Sports Med* 2006;25:279-92.
14. Seldes RM, Tan V, Hunt J, Katz M, Winiarsky R, Fitzgerald RH Jr. Anatomy, histologic features, and vascularity of the adult acetabular labrum. *Clin Orthop Relat Res* 2001;382:232-40.
15. Hunt D, Clohisy J, Prather H. Acetabular tears of the hip in women. *Phys Med Rehabil Clin N Am* 2007;18:497-520.
16. Narvani AA, Tsiridis E, Tai CC, Thomas P. Acetabular labrum and its tears. *Br J Sports Med* 2003;37:207-11.
17. Trisolino G, Favero M, Dallari D, Tassinari E, Traina F, Otero M, *et al.* Labral calcification plays a key role in hip pain and symptoms in femoroacetabular impingement. *J Orthop Surg Res* 2020;15:86.
18. Domzalski ME, Synder M, Karauda A, Papierz W. Histological changes of the acetabular labrum in coxarthrosis: Labral degeneration and repair. *Hip Int* 2017;27:66-73.
19. Robertson WJ, Kadrmaz WR, Kelly BT. Arthroscopic management of labral tears in the hip: A systematic review. *Clin Orthop Relat Res* 2007;455:88-92.
20. McCarthy JC, Noble P, Schuck M, Alusio FV, Wright J, Lee J. Acetabular and labral pathology. In: *Early hip disorders*. New York: Springer Verlag; 2003.
21. Keeney JA, Peelle MW, Jackson J, Rubin D, Maloney WJ, Clohisy JC. Magnetic resonance arthrography versus arthroscopy in the evaluation of articular hip pathology. *Clin Orthop Relat Res* 2004;429:163-9.
22. Cotten A, Boutry N, Demondion X, Paret C, Dewatre F, Liesse A, *et al.* Acetabular labrum: MRI in asymptomatic volunteers. *J Comput Assist Tomogr* 1998;22:1-7.
23. Smith TO, Hilton G, Toms AP, Donell ST, Hing CB. The diagnostic accuracy of acetabular labral tears using magnetic resonance imaging and magnetic resonance arthrography: A meta-analysis. *Eur Radiol* 2011;21:863-74.
24. Studler U, Kalberer F, Leunig M, Zanetti M, Hodler J, Dora C, *et al.* MR Arthrography of the hip: Differentiation between an anterior sublabral recess as a normal variant and a labral tear. *Radiology* 2008;249:947-54.
25. Bruce W, Van Der Wall H, Storey G, Loneragan R, Pitsis G, Kannangara S. Bone scintigraphy in acetabular labral tears. *Clin Nucl Med* 2004;29:465-8.
26. Byrd JW, Jones K. Diagnostic accuracy of clinical assessment, magnetic resonance imaging, magnetic resonance arthrography, and intra-articular injection in hip arthroscopy patients. *Am J Sports Med* 2004;32:1668-74.
27. Rakhra KS. Magnetic resonance imaging of acetabular labral tears. *J Bone Joint Surg Am* 2011;93:28-34.
28. Loeser RF. Molecular mechanisms of cartilage destruction: Mechanics, inflammatory mediators, and aging collide. *Arthritis Rheum* 2006;54:1357-60.
29. Samuels J, Krasnokutsky S, Abramson SB. Osteoarthritis: A tale of three tissues. *Bull NYU Hosp Jt Dis* 2008;66:244-50.
30. Sellam J, Berenbaum F. The role of synovitis in pathophysiology and clinical symptoms of osteoarthritis. *Nat Rev Rheumatol* 2010;6:625-35.
31. Koyama T, Uchida K, Fukushima K, Ohashi Y, Uchiyama K, Inoue G, *et al.* Elevated levels of TNF- α , IL-1 β and IL-6 in the synovial tissue of patients with labral tear: A comparative study with hip osteoarthritis. *BMC Musculoskelet Disord* 2021;22:33.

How to cite this article: Saad A, Mayne AIW, Iyengar KP, Wall P, Politis A, Bache CE, *et al.* The prevalence of synovitis during hip arthroscopy for labral tears – An observational study. *J Arthrosc Surg Sports Med.* 2025;6:54-7. doi: 10.25259/JASSM_33_2024