

Original Article

# Isolated MPFL reconstruction for recurrent lateral patellar instability in patients with TT-TG distance <25 mm: A calculated safe risk!

Sumant Chacko Verghese<sup>1</sup>, Santosh K. Sahanand<sup>2</sup>, Nikhil Joseph Martin<sup>3</sup>, Abhay Harsh Kerketta<sup>4</sup>, Prashanth Chalasani<sup>5</sup>, David V. Rajan<sup>2</sup>

<sup>1</sup>Department of Orthopaedics, KMCH Institute of Health Sciences and Research, Coimbatore, Tamil Nadu, <sup>2</sup>Department of Arthroscopy and Sports Medicine, OrthoOne Orthopaedic Speciality Center, Coimbatore, Tamil Nadu, <sup>3</sup>Department of Orthopaedics, Muvattupuzha Co-operative Super Speciality Hospital, Cochin, Kerala, <sup>4</sup>Department of Orthopaedics, Manipal Tata Medical College, Jamshedpur, Jharkhand, <sup>5</sup>Department of Orthopaedics, Ramesh Hospitals, Guntur, Andhra Pradesh, India.

## ABSTRACT

**Objectives:** The objectives of the study were to describe the surgical technique of our modification of isolated medial patellofemoral ligament (MPFL) reconstruction, in patients with patellar instability. As per literature, isolated MPFL reconstruction is advocated if tibial tubercle-trochlear groove (TT-TG) <20 mm. Our study proposes isolated MPFL reconstruction in patients with TT-TG <25 mm and aims to determine any predisposing anatomic variants to aid in the treatment algorithm.

**Materials and Methods:** A retrospective analysis of 52 patients with patellar instability (TT-TG <25 mm), who underwent isolated MPFL reconstruction was undertaken. The study population was divided into two groups; TT-TG <20 mm and TT-TG = 20–24 mm. Both groups were assessed radiologically and on the basis of clinical and functional outcome (KUJALA score), over 5-year follow-up period.

**Results:** The mean age of the study population was 21.98 years, with a female (63.5%) majority. Among the 52 patients included in the study, 39 patients (75%) had TT-TG <20 mm and 13 patients (25%) had TT-TG = 20–24 mm. We noticed statistically significant improvement in both groups with respect to clinical and functional outcome, with no reported complications. None of the patients had patella alta or high grades of trochlear dysplasia.

**Conclusion:** MPFL reconstruction without concomitant bony procedures can be safely performed in patients with a TT-TG <25 mm, in the absence of patella alta or high-grade trochlear dysplasia. Our modification of isolated MPFL reconstruction has shown excellent long-term results. In addition, our technique uses only a single interference screw, thereby reducing cost of surgery and implant hardware.

**Keywords:** Patellar instability, Surgical technique, Medial patellofemoral ligament reconstruction, Tibial tubercle-trochlear groove distance, Functional outcome

## INTRODUCTION

Patellofemoral dislocations are common and arise due to contraction of the quadriceps muscle across a flexed, valgus knee with the tibia externally rotated with respect to the femur. The principal medial stabilizer of the patella between 0 and 30° of knee flexion is the medial patellofemoral ligament (MPFL), which functions as a restraint to lateral patellar translation and is consequently damaged in 96% of the patients with lateral patellar instability.<sup>[1]</sup> As patellofemoral instability may lead to the disruption of medial-sided soft tissues, MPFL reconstruction has become the cornerstone among those warranting surgery, with numerous recent studies reporting improvement in functional outcomes,

diminished recurrence and complication rates, and superior patient satisfaction.<sup>[2]</sup>

In the recent past, there has been much controversy surrounding the need for MPFL reconstruction along with concomitant bony procedures in patients with raised tibial tubercle-trochlear groove (TT-TG) distance or with higher grades of trochlear dysplasia. The treatment algorithm for the latter includes trochleoplasty which is a technically challenging surgery, with moderate results and a higher incidence of osteoarthritic changes overtime.<sup>[3,4]</sup> A concomitant tibial-tubercle osteotomy (TTO) in patients with increased TT-TG distance is widely practiced and advocated by numerous studies.<sup>[5,6]</sup> Many have strived to bring to light

\*Corresponding author: Santosh K. Sahanand, Department of Arthroscopy and Sports Medicine, OrthoOne Orthopaedic Speciality Center, Coimbatore, Tamil Nadu, India. sahanand@gmail.com

Received: 02 June 2021 Accepted: 02 August 2021 EPub Ahead of Print: 30 December 2021 Published: XXXXXX DOI 10.25259/JASSM\_22\_2021

This is an open-access article distributed under the terms of the Creative Commons Attribution-Non Commercial-Share Alike 4.0 License, which allows others to remix, tweak, and build upon the work non-commercially, as long as the author is credited and the new creations are licensed under the identical terms. ©2021 Published by Scientific Scholar on behalf of Journal of Arthroscopic Surgery and Sports Medicine

those patients who would profit the most from a concomitant TTO on the basis of anatomic risk factors, such as trochlear dysplasia, TT-TG distance, TT-posterior cruciate ligament (TT-PCL) distance, patella alta, and patellar tilt.<sup>[7,8]</sup> Among these, the chief anatomic predisposing factor is trochlear dysplasia, succeeded by lateral patellar tilt of  $>20^\circ$ .<sup>[7,9]</sup> With respect to TT-TG and TT-PCL distance, there are multiple studies advising a concomitant TTO when the distance is  $>20$  mm and  $>24$  mm, respectively.<sup>[8,10]</sup> The purpose of this study was to describe our modification of isolated MPFL reconstruction surgical technique: Transosseous single loop suture technique, in patients with TT-TG distance  $<25$  mm and report its clinical and functional outcomes along with the instability recurrence rate over a long-term follow-up of 5 years.

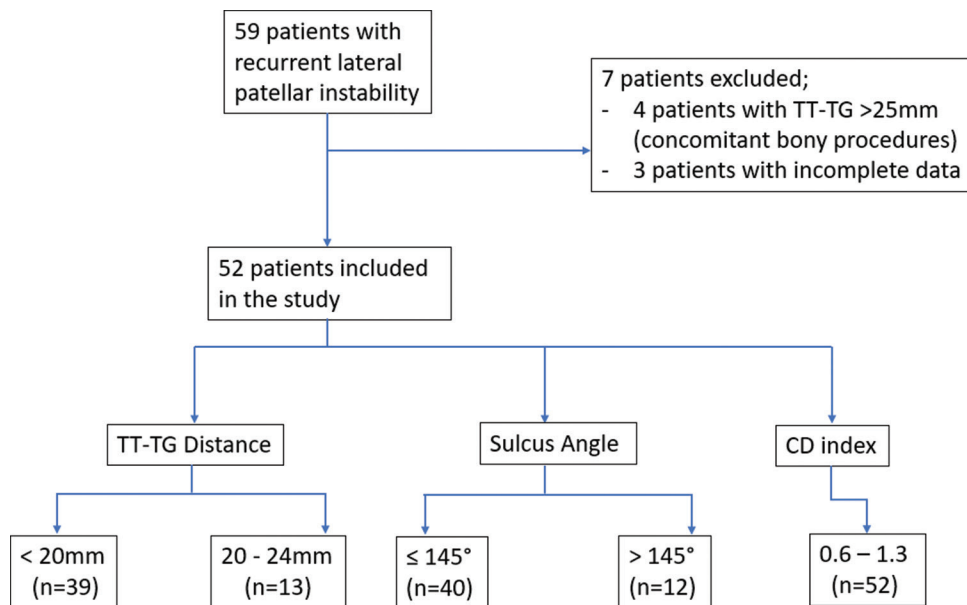
**MATERIALS AND METHODS**

An institutional proposal was approved by the Ethical Committee board (Ref: Project No: 2/F/2021) to retrospectively evaluate all patients with patellar instability at our center. The study population included patients with recurrent lateral patellar instability who underwent isolated MPFL reconstruction from January 2013 to March 2016. All patients underwent our modification of isolated MPFL reconstruction: Transosseous single loop suture technique and were operated by the same surgeon. All patients were followed up to a duration of 5 years post-surgery. The data were collected from the case sheets of the patients from the registry of the medicals record department of our hospital. The case sheets included patient’s history and presenting complaints along with examination findings, pre-operative

knee scores (KUJALA score), pre-operative radiological investigations (X-rays, MRI, and CT scan), details of the surgery, and discharge summary. Pre-operative radiological findings (X-ray, MRI scan, and CT scan) were noted from the cases sheets including lateralization of TT (TT-TG distance), patellar height (Caton-Deschamps index), and trochlear dysplasia (sulcus angle, trochlear depth, and trochlear inclination). The case sheets also included follow-up of these patients in the OPD with documentation of post-operative KUJALA scores.

**Study design**

A total of 59 patients were operated at our center from January 2013 to March 2016. Patients with TT-TG distance  $\geq 25$  mm or high-grade (Dejour Type-C and Dejour Type-D classification) trochlear dysplasia, who underwent concomitant bony procedures such as TTO and trochleoplasty were excluded from the study. Patients with incomplete data (radiological parameters or pre-operative KUJALA score) were also excluded from the study. Four patients had concomitant bony surgical procedures and three patient’s case sheets had incomplete data, and were excluded from the study. Fifty-two patients underwent isolated MPFL reconstruction and were included in this study as depicted in the flowchart [Figure 1]. The 52 patients were then divided into two groups, patients with TT-TG distance  $<20$  mm and those with a TT-TG distance from 20 to 24 mm. Both groups were then assessed in terms of radiological parameters such as CD index, sulcus angle, trochlear inclination, and depth to check for a statistically significant association. The two groups were then evaluated on the basis of KUJALA score



**Figure 1:** Flowchart illustrating the study population which was included in the study. The patients were divided into two groups on the basis of TT-TG distance; 39 patients with TT-TG. TT-TG: Tibial tubercle-trochlear groove.

preoperatively, at 1-year post-operative and at 5-year post-operative. The improvement in clinical and functional outcome (on the basis of KUJALA scoring) between the two groups was assessed to check for statistically significant association.

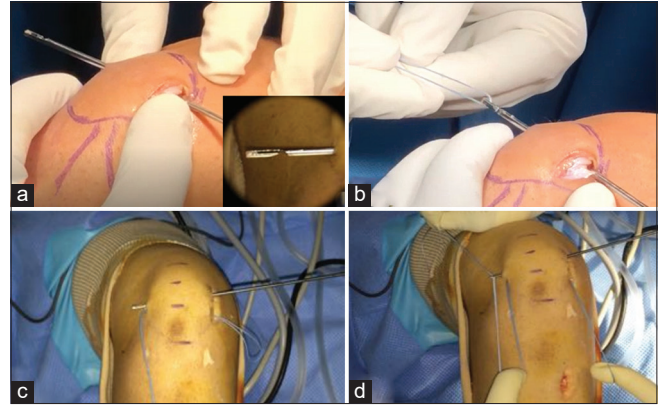
### Statistical analysis

The data were entered into Excel and were analyzed using SPSS-26 software. Categorical variables were presented as frequency and percentages, continuous variables were presented as mean  $\pm$  standard deviation. Independent sample *t*-test was used to measure the association between the vitals at different times. Association between the categorical variables was measured using Chi-square/Fisher's exact test.  $P < 0.05$  was considered as statistically significant.

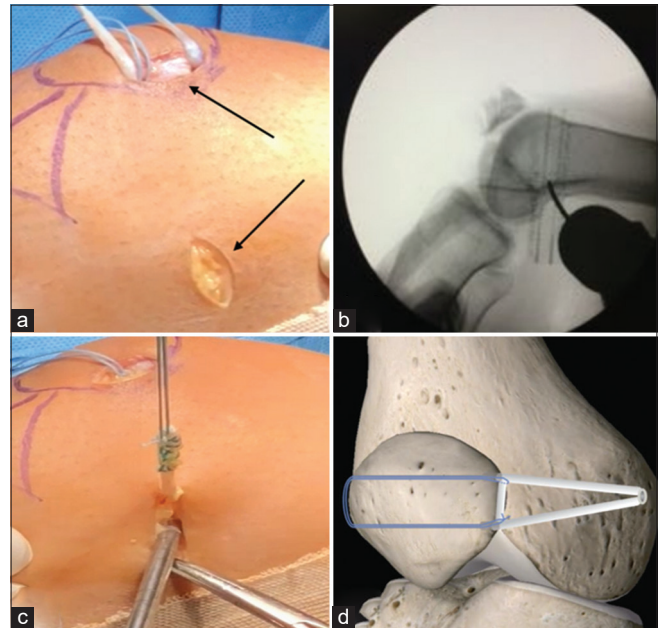
### Surgical technique

Patients are placed supine, and spinal anesthesia was administered. A non-sterile tourniquet was used. Limb preparation and draping were done as per protocol, following which a diagnostic knee arthroscopy is performed to inspect the knee, check for associated lesions, patellar glide, and tracking. The tourniquet is then inflated, and the gracilis tendon is harvested. The two ends of the graft are each sutured with No: 2 FiberWire using a whipstitch technique up to 1 inch from each end. A 2 cm horizontal skin incision is made on the medial aspect middle-third of patella. Two parallel tunnels are made with 2.5 mm drill under fluoroscopic guidance. Two tunnels are placed at the junction of upper-middle and middle-lower 1/3<sup>rd</sup> of the patella. While placing the two tunnels, care is taken to avoid convergence/ divergence of tunnels and penetration of articular/ superior surface of patella. A 2.5 mm open-ended beath pin is passed through the distal tunnel and a small nick is made over the skin for the beath pin to pass out laterally as shown in [Figure 2a]. Ethibond No: 5 suture is doubled on its length to form a loop and the loop end is loaded onto the pin laterally and retrieved back through the tunnel medially [Figure 2b]. A second closed-end beath pin is passed through the 2<sup>nd</sup> proximal tunnel and exits through the skin through same incision laterally [Figure 2c]. The two free ends of the Ethibond suture are loaded onto the beath pin and retrieved medially [Figure 2d].

The retinacular tissue between the tunnels is removed with a nibbler to create a crater for the graft to lie. The central part of the graft is loaded into the suture loop and placed within the crater and simple knots are applied over the free ends of the suture to secure the graft onto the medial patellar facet [Figure 3a, top arrow]. Clinically, palpate the medial epicondyle and adductor tubercle prior to making the incision. A 2 cm vertical skin incision is made between the two points [Figure 3a, bottom arrow]. The soft tissue is dissected, and medial epicondyle is palpated which is felt as a soft bump whereas the adductor tubercle is felt as a



**Figure 2:** (a) An open-ended beath pin (inner box) is passed through the distal tunnel from medial-to-lateral direction and exited through a small nick made laterally. (b) No: 5 Ethibond suture is doubled on its length to form a loop, loaded onto the pin laterally and retrieved back through the tunnel medially. (c) A closed-end beath pin is passed through the proximal tunnel. (d) The two free ends of the Ethibond suture which was fashioned into a loop are now loaded onto the closed end of the beath pin and retrieved medially.



**Figure 3:** (a) Top arrow denotes the graft lying within the crater created along medial aspect of the patella, bottom arrow shows in the incision for the femoral tunnel. (b) C-arm images of fluoroscopic guidance while drilling the femoral tunnel. (c) The graft is passed from the patellar incision to the femoral incision through created plane between retinaculum and capsule. (d) 3-D animated representation of our technique which shows the transosseous single loop suture technique.

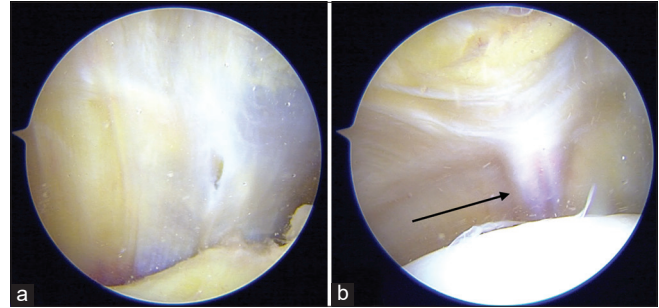
pointed bump. Midway between the two bony landmarks is the Schottle's point, which is confirmed under fluoroscopic guidance [Figure 3b]. A 2.5 mm beath pin is drilled from

the Schottle's point with the beath pin directed proximally and anteriorly. To check for isometric position of the drilled beath pin, the threads of the graft are passed around the pin (over the skin) and flexion-extension movements of the knee is performed. During flexion-extension movements, the graft should not move more than 1 cm, which indicates that location of pin is isometric. Graft isometry is checked first in extension and then in flexion. If there is >1 cm of graft excursion during the range of motion, the position of the pin must be adjusted accordingly.

A plane is then dissected between the retinaculum and capsule for graft passage between the two incisions. The graft is then passed through this plane [Figure 3c]. A reamer of size equivalent to the measured diameter of graft (most commonly, size 6mm reamer) is drilled over the beath pin from medial to lateral direction. Next, the threads of the graft are loaded onto the open end of the beath pin and pulled out laterally. To avoid overtightening of graft while fixing the femoral end, a cinch knot is placed on the graft 1 cm from femoral entry point and traction is given on this cinch thread while passing the femoral interference screw. This helps to prevent subsidence of graft into the femoral tunnel along with the screw, thereby avoiding overtightening. Next, lateral patellar restraint is checked in complete extension where a two-quadrant lateral patellar glide must be maintained. Over tightening may cause medial knee pain and should be avoided. With various degrees of flexion-extension movements, patellar tracking within the TG and lateral patellar restraint is sequentially assessed. With the knee in 60° of flexion, guide wire is passed through the femoral tunnel. The graft is fixed within the femoral tunnel using an interference screw. The diameter of screw will be one size more than the graft diameter, that is, for a 6 mm graft diameter, screw will be of 7 mm. The length of the screw is kept constant for all cases of length 30 mm. An animated representation of the suture loop with graft along the medial aspect of patella, with an interference screw within the femoral tunnel has been represented in [Figure 3d]. Extra-articular graft placement is confirmed in arthroscopy. Arthroscopic intraoperative images of pre- and post-MPFL reconstruction as illustrated in [Figure 4a and b] to confirm extra-articular graft placement. The wounds are thoroughly irrigated and subcutaneous tissue is closed with No: 2 Vicryl and skin with No: 3 Ethilon. Long knee brace is applied after dressing is done on the OT table itself and is to be continued for 2 weeks.

## RESULTS

Among the 52 knees which were evaluated, majority of the patients were female (63.5%) and the remaining were male. There was a single case of bilateral MPFL tear, and isolated MPFL reconstruction was done bilaterally in the same sitting. The mean age of the study population was 21.98 years



**Figure 4:** (a) Diagnostic arthroscopy at the start of the surgery, pointing toward the medial capsule of the knee. (b) Diagnostic arthroscopy is repeated after MPFL reconstruction to confirm extra-articular graft positioning as indicated by the arrow. MPFL: Medial patellofemoral ligament.

ranging from 12 to 37 years. The study population was divided into two groups based on the pre-operative TT-TG distance measured on CT scan. Thirty-nine patients had a TT-TG <20 mm and the remaining 13 patients were within a TT-TG distance range between 20 and 24 mm as depicted in [Table 1]. We were unable to determine any statistically significant difference between the two groups with respect to the other radiological parameters, that is, CD index, sulcus angle, trochlear inclination, and depth. There were 12 patients with a sulcus angle >145°, out of which 10 of these patients were classified on CT scan as Dejour Type-A and the remaining two patients as Dejour Type-B grade of trochlear dysplasia. All 52 patients in the study had a CD index ≤1.3, with a mean CD index of 1.12 which is within the normal range.

Pre-operative, 1-year post-operative, and 5-year post-operative Kujala scores were compared between the two groups. We noticed an increase in Kujala scores which were consistent in both groups and found to be statistically significant ( $P = 0.003$ ). At 1-year follow-up, we noticed that patients with a TT-TG distance <20 mm had a higher Kujala score as depicted in [Table 2]. However, at 5-year follow-up, both groups had similar Kujala scores, as shown in [Table 3].

## DISCUSSION

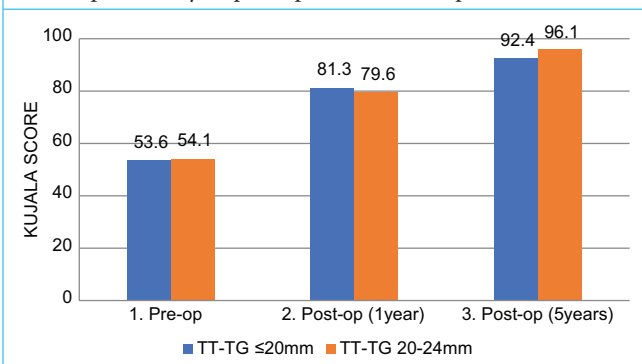
Studies highlighting the anatomy of the knee, have precisely illustrated the medial-sided structures. The function of the MPFL during 0–30° of knee flexion as a medial restraint to lateral subluxation has been clearly outlined.<sup>[11,12]</sup> The TG contributes to additional patellar stability with increased knee flexion.<sup>[12]</sup> In the last decade, several surgical procedures have been described to address each of these anatomic variants predisposing to lateral patellar instability. Varying techniques of MPFL reconstruction have replaced MPFL repair, as it restores the most vital soft-tissue restraint during early flexion. However, the indication for a concomitant TT transfer remains debatable. The need for a TTO depends

**Table 1:** The mean radiological parameters between both groups.

Radiological parameters	TT-TG<20 mm (n=39)		TT-TG 20–24 mm (n=13)		t-value	P-value
	Mean	Std. deviation	Mean	Std. deviation		
CD index	1.28	0.33	1.26	0.38	0.163	0.871
Sulcus angle	137.4°	11.41	135.1°	15.44	0.577	0.567
Trochlear inclination	21.9°	7.52	23.6°	8.86	-0.654	0.516
Trochlear depth	4.3 mm	1.95	3.9 mm	2.25	0.654	0.516

**Table 2:** The mean increase in KUJALA scores at subsequent follow-ups. Patients with TT-TG<20 mm had a higher KUJALA score at the end of 1-year post-surgery. At the end of 5 years, both groups of patients had similar KUJALA scores.

KUJALA scores	TT-TG<20 mm (n=39)		TT-TG 20–24 mm (n=13)	
	Mean increase in KUJALA score	Standard deviation	Mean increase in KUJALA score	Standard deviation
Pre-operative				
→	27.21	20.13	25.46	24.84
Post-operative 1 year				
→	11.07	11.05	16.53	8.75
Post-operative 5 years				

**Table 3:** The KUJALA score between the two groups in three different scenarios; (1) before surgery, (2) at 1-year post-operative follow-up, (3) at 5-year post-operative follow-up.

on the amount of lateralization of the TT which can be evaluated by two measurements, that is, TT-TG distance or TT-PCL distance. Although TT-PCL has been widely used in the recent past due to its growing popularity, a recent study supports the use of TT-TG distance over TT-PCL distance, as it is more reliable measurement with insignificant intraobserver variations.<sup>[13]</sup> Consequently, in this study, we have preferred TT-TG distance over TT-PCL distance. Previously, TTO was advocated if TT-TG distance >15 mm.<sup>[14]</sup> Numerous studies have recently reported excellent functional outcomes, even without a concomitant bony procedure, in patients with TT-TG distance <20 mm. Howells *et al.* did not report any case of recurrent dislocation in 193 patients who underwent isolated MPFL reconstruction with a TT-TG distance of 15–20 mm.<sup>[15]</sup> Wagner *et al.* reported similar

findings with isolated MPFL reconstruction, although, they noticed poorer scores in patients with TT-TG distance >20 mm.<sup>[16]</sup> At present, the indications for an isolated MPFL reconstruction which is most commonly followed by orthopedic surgeons around the world are; a normal TT-TG (<20 mm), a normal or Dejour Type-A/Type-B trochlea, and a CD index measurement of <1.3 indicating no patella alta.<sup>[17]</sup> Although clinical and functional outcomes of a combined procedure showed promising results, there was a consequential increase in morbidity due to an additional tibial tuberosity transfer.<sup>[18–20]</sup> Performing a TTO not only increases the operating time but also significantly alters the rehabilitation protocol with respect to immediate post-operative weight-bearing.<sup>[18]</sup> Accordingly, it would be best to avoid an additional procedure without compromising the results.

We divided the study population into two groups based on the TT-TG distance, wherein, 39 patients had a TT-TG distance <20 mm and 13 patients had a TT-TG distance of 20–24 mm. Both sets of groups were followed up and evaluated on the basis of patient-related outcomes measure scores, that is, KUJALA scores. There was a statistically significant (*P*-value 0.003) increase in KUJALA scores which was comparable among both groups at the end of 1-year and 5-year follow-ups, as depicted in [Table 3]. Our study yields similar results to the previous studies which yields satisfactory clinical outcomes in those patients with a TT-TG distance >20 mm.<sup>[15,16]</sup> However, we also noticed that none of the 13 patients had high-grade trochlear dysplasia or patella alta. The mean sulcus angle and trochlear depth in these 13 patients were 135.1° and 4.3 mm, respectively, and the mean CD index was 1.26.

Among the 52 patients included in the study, 12 patients had a sulcus angle  $>145^\circ$ . However, we noticed that these patients could be classified as either Type A (10 patients) or Type B (two patients) of Dejour classification of trochlear dysplasia. None of the patients in the study who underwent isolated MPFL reconstruction had higher grades (Type C or Type D) of trochlear dysplasia. All 52 patients in the study had a CD index  $\leq 1.3$  with a mean CD index of 1.12, which indicates that none of the patients in the study had patella alta. This suggests that it is more arguably an amalgamation of predisposing factors rather than a sole parameter, such as TT-TG distance, which would determine those patients who would benefit from a concomitant bony procedure. None of the 13 patients in our study with TT-TG distance of  $>20$  mm had any episode of recurrent dislocation, or, any other morbid complication. This implies that the TT-TG is not the chief component in determining functional outcomes and that the configuration of the TG plays a more important role than other predisposing factors, most importantly TT-TG distance. This study is, however, not without limitations. Among the 52 knees included in the study, only 13 knees have a TT-TG distance of 20–24 mm. Even though statistical significance was obtained with the current study population, further research with larger numbers and longer follow-ups will help to strengthen our conclusion.

## CONCLUSION

To the best of our knowledge, literature advocates concomitant bony procedures along with MPFL reconstruction for recurrent lateral patellar instability in those patients with a TT-TG distance  $>20$  mm. Our study provides sufficient evidence to indicate that TT-TG distance on its own does not dictate the treatment algorithm. Our modification of isolated MPFL reconstruction with a transosseous single loop suture technique can be safely performed in recurrent lateral patellar instability with a TT-TG distance  $<25$  mm in the absence of patella alta and higher grades of trochlear dysplasia. Our technique has shown excellent results with significant improvement in functional and clinical outcomes (KUJALA score) in patients with TT-TG distance of 20–24 mm, which is similar to the patients with a TT-TG distance  $<20$  mm. Moreover, our modification of the technique uses only a single interference screw and considerably reduces the cost of treatment along with implant hardware used.

## Ethical approval

Before the start of the study, ethical clearance was obtained from the Institutional Human Ethics Committee (IHEC) (Ref: Project No: 2/F/2021).

## Declaration of patient consent

The Institutional Review Board (IRB) permission obtained for the study.

## Financial support and sponsorship

Nil.

## Conflicts of interest

There are no conflicts of interest.

## REFERENCES

- Zaffagnini S, Colle F, Lopomo N, Sharma B, Bignozzi S, Dejour D, *et al.* The influence of medial patellofemoral ligament on patellofemoral joint kinematics and patellar stability. *Knee Surg Sports Traumatol Arthrosc* 2013;21:2164-71.
- Stupay KL, Swart E, Stein BE. Widespread implementation of medial patellofemoral ligament reconstruction for recurrent patellar instability maintains functional outcomes at midterm to long-term follow-up while decreasing complication rates: A systematic review. *Arthroscopy* 2015;31:1372-80.
- Rouanet T, Gougeon F, Fayard JM, Remy F, Migaud H, Pasquier G. Sulcus deepening trochleoplasty for patellofemoral instability: A series of 34 cases after 15 years postoperative follow-up. *Orthop Traumatol Surg Res* 2015;101:443-7.
- Weber AE, Nathani A, Dines JS, Allen AA, Shubin-Stein BE, Arendt EA, *et al.* An algorithmic approach to the management of recurrent lateral patellar dislocation. *J Bone Joint Surg Am* 2016;98:417-27.
- Middleton KK, Gruber S, Stein BE. Why and where to move the tibial tubercle: Indications and techniques for tibial tubercle osteotomy. *Sports Med Arthrosc Rev* 2019;27:154-60.
- Ferrari MB, Sanchez G, Kennedy NI, Sanchez A, Schantz K, Provencher MT. Osteotomy of the tibial tubercle for anteromedialization. *Arthrosc Tech* 2017;6:e1341-6.
- Askenberger M, Janarv PM, Finnbogason T, Arendt EA. Morphology and anatomic patellar instability risk factors in first-time traumatic lateral patellar dislocations: A prospective magnetic resonance imaging study in skeletally immature children. *Am J Sports Med* 2017;45:50-8.
- Clifton B, Richter DL, Tandberg D, Ferguson M, Treme G. Evaluation of the tibial tubercle to posterior cruciate ligament distance in a pediatric patient population. *J Pediatr Orthop* 2017;37:e388-93.
- Sanders TL, Pareek A, Hewett TE, Stuart MJ, Dahm DL, Krych AJ. Incidence of first-time lateral patellar dislocation: A 21-year population-based study. *Sports Health* 2018;10:146-51.
- Christensen TC, Sanders TL, Pareek A, Mohan R, Dahm DL, Krych AJ. Risk factors and time to recurrent ipsilateral and contralateral patellar dislocations. *Am J Sports Med* 2017;45:2105-10.
- LaPrade RF, Engebretsen AH, Ly TV, Johansen S, Wentorf FA, Engebretsen L. The anatomy of the medial part of the knee. *J Bone Joint Surg Am* 2007;89:2000-10.
- Stephen JM, Lumpaopong P, Deehan DJ, Kader D, Amis AA. The medial patellofemoral ligament: Location of femoral attachment and length change patterns resulting from anatomic and nonanatomic attachments. *Am J Sports Med* 2012;40:1871-9.
- Brady JM, Sullivan JP, Nguyen J, Mintz D, Green DW, Strickland S, *et al.* The tibial tubercle-to-trochlear groove distance is reliable in the setting of trochlear dysplasia, and superior to the tibial tubercle-to-posterior cruciate ligament distance when evaluating coronal malalignment in patellofemoral instability. *Arthroscopy* 2017;33:2026-34.
- Schöttle PB, Fucentese SF, Romero J. Clinical and radiological outcome of medial patellofemoral ligament reconstruction with a semitendinosus autograft for patella instability. *Knee Surg Sports Traumatol Arthrosc* 2005;13:516-21.
- Howells NR, Barnett AJ, Ahearn N, Ansari A, Eldridge JD. Medial patellofemoral ligament reconstruction: A prospective outcome assessment of a large single centre series. *J Bone Joint Surg Br* 2012;94:1202-8.
- Wagner D, Pfalzer F, Hingelbaum S, Huth J, Mauch F, Bauer G. The influence of risk factors on clinical outcomes following anatomical medial patellofemoral ligament (MPFL) reconstruction using the gracilis tendon. *Knee Surg Sports Traumatol Arthrosc* 2013;21:318-24.
- Ahmad R, Calciu M, Jayasekera N, Schranz P, Mandalia V. Combined medial patellofemoral ligament reconstruction and tibial tubercle transfer

- results at a follow-up of 2 years. *J Knee Surg* 2017;30:42-6.
18. Krych AJ, O'Malley MP, Johnson NR, Mohan R, Hewett TE, Stuart MJ, *et al.* Functional testing and return to sport following stabilization surgery for recurrent lateral patellar instability in competitive athletes. *Knee Surg Sports Traumatol Arthrosc* 2018;26:711-8.
  19. Biedert RM, Albrecht S. The patellotrochlear index: A new index for assessing patellar height. *Knee Surg Sports Traumatol Arthrosc* 2006;14:707-12.
  20. Hopper GP, Leach WJ, Rooney BP, Walker CR, Blyth MJ. Does degree of trochlear dysplasia and position of femoral tunnel influence outcome

after medial patellofemoral ligament reconstruction? *Am J Sports Med* 2014;42:716-22.

**How to cite this article:** Verghese SC, Sahanand SK, Martin NJ, Kerketta AH, Chalasani P, Rajan DV. Isolated MPFL reconstruction for recurrent lateral patellar instability in patients with TT-TG distance <25 mm: A calculated safe risk! *J Arthrosc Surg Sports Med*, doi.10.25259/JASSM\_22\_2021