

Original Article

Functional and structural outcomes of arthroscopic single-row repair in full-thickness rotator cuff tears

Jaimeen Pravinkumar Jesalpura¹, Shailin Asitkumar Shah¹, Vikas Vinodchandra Patel¹

¹Department of Orthopedics, Vaishvi Orthopedic Hospital, Vadodara, Gujarat, India.

ABSTRACT

Objectives: This study evaluates the functional outcomes and structural integrity following single-row (SR) arthroscopic repair in patients with full-thickness rotator cuff tears. The influence of pre-operative fatty atrophy and tear size on post-operative outcomes is also analyzed to determine their prognostic significance.

Materials and Methods: Sixty patients who underwent SR arthroscopic rotator cuff repair were followed for a minimum of 24 months (mean follow-up: 35.93 ± 26.24 months). Functional outcomes were assessed using the Constant-Murley Score (CMS) and the University of California, Los Angeles (UCLA) score. Structural integrity was evaluated through ultrasonography using the Sugaya classification. The impact of tear size and fatty infiltration on post-operative outcomes was analyzed.

Results: Significant improvements were observed postoperatively. The mean CMS improved to 94.83 ± 7.78 ($P < 0.001$), and the mean UCLA score increased to 33.82 ± 6.7 ($P < 0.001$). Active forward flexion, external rotation, and muscle strength improved significantly, while pain scores decreased (Visual analog scale: 1.2 ± 0.75, $P < 0.001$). Structural assessment revealed 85% of patients with Sugaya type I repairs (mean CMS: 97.06 ± 5.21), 10% with type II (CMS: 82.67 ± 9.42), and 5% with type III or higher (CMS: 81.33 ± 6.35), all statistically significant ($P < 0.001$). Tear size and fatty atrophy did not significantly affect functional outcomes.

Conclusion: SR arthroscopic repair for full-thickness rotator cuff tears yields excellent functional results and tendon healing at a minimum follow-up of 24 months. Superior outcomes were associated with intact tendon healing. Pre-operative tear size and fatty atrophy were not significant predictors of post-operative function.

Keywords: Arthroscopic repair, Fatty atrophy, Functional outcomes, Rotator cuff tear, Structural integrity, Tear size

INTRODUCTION

Background/rationale

Rotator cuff tears are a common cause of shoulder pain and dysfunction, with an incidence ranging from 4% to 32% and increasing prevalence with age. These tears can lead to muscle weakness and altered glenohumeral kinematics, significantly impacting quality of life. In developing countries such as India, financial constraints often complicate optimal management strategies.

Non-surgical treatment may be considered initially; however, evidence suggests superior outcomes following surgical repair. Van Der Meijden *et al.* reported that patients with an intact rotator cuff postoperatively demonstrate significantly better functional outcomes compared to those with re-tears.^[1] Arthroscopic rotator cuff repair (ARCR) has

become the preferred surgical technique over open repair, as noted by Davey *et al.*, due to its advantages, including reduced post-operative pain, shorter hospitalization, quicker rehabilitation, and improved cosmetic results.^[2]

Although surgical techniques have evolved from single-row (SR) to double-row (DR) and transosseous-equivalent repairs aiming to restore the anatomical footprint and enhance tendon-to-bone healing, clinical outcomes remain comparable. As Vecchini *et al.* highlighted, these advanced techniques incur higher implant costs without providing significant clinical or functional benefits over SR repair.^[3]

Despite surgical advancements, post-operative re-tears remain a concern, potentially leading to persistent pain and suboptimal recovery of shoulder strength. This underscores the need for a cost-effective yet reliable surgical approach.

*Corresponding author: Jaimeen Pravinkumar Jesalpura, Department of Orthopedics, Vaishvi Orthopedic Hospital, Vadodara, Gujarat, India. vaishviortho@gmail.com

Received: 11 April 2025 Accepted: 28 April 2025 EPub Ahead of Print: 11 June 2025 Published: 09 January 2026 DOI: 10.25259/JASSM_20_2025

This is an open-access article distributed under the terms of the Creative Commons Attribution-Non Commercial-Share Alike 4.0 License, which allows others to remix, transform, and build upon the work non-commercially, as long as the author is credited and the new creations are licensed under the identical terms. ©2026 Published by Scientific Scholar on behalf of Journal of Arthroscopic Surgery and Sports Medicine

Objective

This study aims to evaluate the functional outcomes and structural integrity following SR arthroscopic rotator cuff repair in patients with full-thickness tears. Specifically, it investigates the influence of pre-operative tear size and fatty atrophy on post-operative recovery, with the goal of determining whether these factors significantly affect patient outcomes after SR-ARCR.

MATERIALS AND METHODS

Study design

This was a retrospective monocentric study (Level IV evidence) based on prospectively collected data from 60 patients who underwent SR-ARCR.

Setting

The study was conducted at a tertiary care orthopedic center between January 2019 and December 2022. A total of 65 patients were recruited, with follow-up continuing for a minimum of 24 months.

Surgical technique

All procedures were performed in the beach-chair position (approximately 80° incline) under general anesthesia combined with an interscalene block. Intraoperative tear size was confirmed using a probe. The subacromial space was accessed through a posterolateral portal, followed by bursectomy, decompression, and adhesion release to restore tendon mobility. The cuff footprint was prepared with a motorized shaver, and tendon edges were debrided. Repair was completed using SR fixation with double- or triple-loaded suture anchors. The anchor number was determined based on tear size and configuration.

Figure 1a illustrates a massive full-thickness tear, and Figure 1b demonstrates its repair using the SR technique. Given the biomechanical importance of the deltoid-supraspinatus and subscapularis-infraspinatus as coronal and axial force couples, respectively, their repair was prioritized. Associated long head of the biceps (LHB) pathology, commonly seen with full-thickness tears,^[4-6] was managed with tenotomy in cases of inflammation, as described by Boileau *et al.*^[7]. In cases where tension-free repair was not achievable despite mobilization, the cuff footprint was medialized by less than 8 mm, preserving the abduction moment arm, as suggested by Kim *et al.*^[8].

Post-operative rehabilitation

A structured rehabilitation protocol was implemented to balance early mobility with tissue healing. Passive pendulum and scapular stabilization exercises were encouraged early, while an arm pouch sling was used for 6 weeks. Passive-assisted range of motion (ROM) began at 4 weeks, with isometric deltoid strengthening at 3 weeks. External rotation

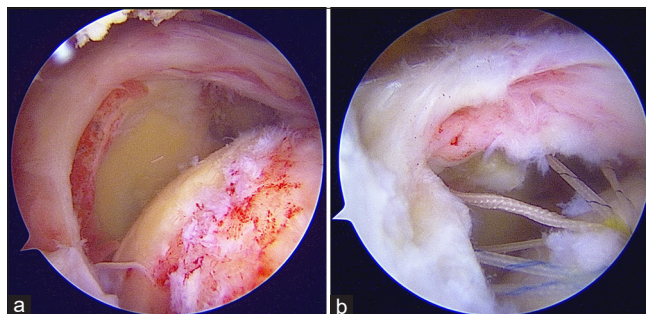


Figure 1: (a) Shows an arthroscopic image of the rotator cuff tear with glenoid with retracted tendons visible, (b) shows sutures taken from rotator cuff and pulling of retracted cuff to the footprint using a single row repair.

exercises were initiated between weeks 3 and 6, and active movements commenced after 6 weeks. Progressive ROM and rotator cuff strengthening continued thereafter. Diabetic patients were maintained in 30° abduction and neutral rotation, with supervised physiotherapy.

Participants

A total of 65 patients were initially included in the study. Five patients were lost to follow-up, leaving 60 patients in the final analysis.

Inclusion criteria

Patients with traumatic or degenerative full-thickness rotator cuff tears and a minimum follow-up of 24 months were included in the study.

Exclusion criteria

Partial-thickness tears, cuff tear arthropathy, or previous shoulder surgery excluded from the study.

Variables

Primary outcomes included structural integrity (Sugaya classification through ultrasonography [US]) and functional outcomes (Constant-Murley Score [CMS], University of California, Los Angeles [UCLA] score, Visual Analog Scale [VAS], and Subjective Shoulder Test [SST]). Predictor variables included age, gender, tear size, and associated procedures. Potential confounders, such as diabetic status and associated LHB pathology, were documented.

All participants underwent surgery by a single experienced surgeon and completed a standardized rehabilitation protocol.

Data sources/management

Demographic and surgical data were extracted from clinical records. Radiographic Acromiohumeral Distance was measured on true anterior-posterior views. Magnetic resonance imaging (MRI) was used to confirm tear size and fatty infiltration, and it was graded using standardized

systems. US was performed at the final follow-up by an experienced musculoskeletal radiologist utilizing a 14 MHz high-frequency linear probe. This modality, as supported by De Jesus *et al.*,^[9] provides a reliable and cost-effective method for evaluating tendon healing. Functional scores were collected pre- and post-operatively.

Bias

To reduce observer bias, imaging assessments were conducted by a single experienced radiologist, and functional scores were evaluated by blinded personnel not involved in surgery.

Study size

Sample size was determined based on the availability of patients undergoing SR-ARCR during the study period with at least 24 months follow-up.

Quantitative variables

Continuous variables such as CMS, VAS, and ROM were treated as continuous in the analysis. Tear size and fatty atrophy were categorized based on established grading systems and analyzed as ordinal variables where appropriate.

Statistical method

Descriptive statistics were used for baseline characteristics. Paired *t*-tests compared pre-operative and post-operative outcomes. One-way analysis of variance was used to assess the effect of tendon integrity and tear size on functional outcomes. Significance was set at $P < 0.05$. Data analysis was performed using the Statistical Package for the Social Sciences.

RESULTS

Participants

(Patients Assessed [$n = 65$]) \rightarrow (Lost to Follow-Up [$n = 5$])
 \rightarrow (Final Analysis [$n = 60$])

Descriptive data

The cohort consisted of 57% females ($n = 34$) and 43% males ($n = 26$). The mean age was 69.2 ± 7.4 years, with 75% of patients aged between 60 and 79 years. The dominant side was affected in 68% ($n = 41$) of cases. Most tears were medium-sized (66.7%, $n = 40$), with small (11.7%, $n = 7$), large (20%, $n = 12$), and massive (1.7%, $n = 1$) tears also represented. Fatty atrophy was most commonly Grade 1 (65%, $n = 39$). Table 1 summarizes the baseline characteristics.

Outcome data

At the final follow-up (mean 35.93 ± 26.24 months), significant improvements were observed:

- Forward flexion: $96.5^\circ \pm 20.98^\circ \rightarrow 166.5^\circ \pm 11.62^\circ$ ($P < 0.001$)
- External rotation: $57.83^\circ \pm 12.63^\circ \rightarrow 79.17^\circ \pm 10.13^\circ$ ($P < 0.001$)

- VAS score: $7.30 \pm 1.14 \rightarrow 1.20 \pm 0.75$ ($P < 0.001$)
- Strength: $10.95 \pm 2.56 \rightarrow 22.78 \pm 3.32$ ($P < 0.001$)

Functional scores significantly improved:

- CMS: $55.03 \pm 9.2 \rightarrow 94.83 \pm 7.78$ ($P < 0.001$)
- UCLA Score: $21.58 \pm 3.5 \rightarrow 33.82 \pm 6.7$ ($P < 0.001$)
- SST Score: $6.03 \pm 1.6 \rightarrow 11.2 \pm 1.8$ ($P < 0.001$)

Table 2 presents clinical outcomes. Table 3 details outcomes stratified by tear size.

Patients with larger tears had marginally lower final scores but still achieved statistically and clinically significant improvements. At the final follow-up, 95% ($n = 57$) of patients had healed tendons (Sugaya grades I - II), and 5% ($n = 3$) had re-tears (Sugaya \geq III). Functional outcomes were significantly superior in the healed group ($P < 0.001$ across all parameters). Table 4 provides a comparative summary of outcomes between healed and re-tear groups.

Main results

Significant improvements were observed in all clinical parameters at the final follow-up. Functional improvements were observed across all tear sizes, with larger tears associated with slightly lower final scores. However, all groups demonstrated statistically significant gains. In patients with small and medium tears, post-operative CMS and UCLA scores were consistently higher than those with large tears, although all groups showed clinically meaningful improvement. Patients with healed cuffs (Sugaya grades 1 and 2) exhibited significantly superior results in pain scores, functional scales, and muscle strength relative to re-tear cases ($P < 0.001$). Patients with healed tendons demonstrated significantly better post-operative outcomes across all functional measures. These findings underscore the importance of achieving tendon integrity in optimizing recovery following SR arthroscopic rotator cuff repair.

Other analyses

Subgroup analysis by tear size and fatty atrophy did not reveal statistically significant differences in final CMS or UCLA scores, suggesting that tendon healing status had a greater influence on outcomes than initial tear characteristics.

DISCUSSION

Key results

The present study demonstrates that arthroscopic SR repair of full-thickness rotator cuff tears provides significant improvements in both functional and structural outcomes. Post-operative gains were observed in active forward flexion, external rotation, muscle strength, and patient-reported scores, including CMS, UCLA Shoulder Score, and SST, with a concurrent reduction in pain levels as measured by the VAS.

SR repair offers advantages such as reduced implant use and lower operative costs, making it especially beneficial

Table 1: Patient demographics (n=60).

Category	Subcategory	Count (n)	Percentage (%)
Sex	Male	26	43.0
	Female	34	57.0
Age (years)	50-59	10	17.0
	60-69	21	35.0
	70-79	24	40.0
	80-89	4	7.0
	90-99	1	1.0
Affected hand	Right	41	68.0
	Left	19	32.0
Fatty atrophy	Type 1	39	65.0
	Type 2	15	25.0
	Type 3	6	10.0
Tear size	Small	7	11.67
	Medium	40	66.67
	Large	12	20.0
	Massive	1	1.67

in resource-limited settings. Consistent with our findings, Huang *et al.*,^[10,11] in a systematic review, reported that arthroscopic repair offers comparable clinical outcomes to mini-open techniques, with added benefits of decreased fibrous ankylosis and improved ROM. Mazzocca *et al.*^[12] demonstrated similar mechanical performance between SR and DR repairs during cyclic loading, with both constructs withstanding over 250 N before failure. Furthermore, Nicholas *et al.*,^[13] through a randomized controlled trial, reported excellent outcomes for both SR and DR techniques, with no clinically significant superiority.

A meta-analysis by Faulkner *et al.*^[14] revealed a higher frequency of type II failures near the musculotendinous junction in DR repairs compared to SR techniques. In addition, SR repair using triple-loaded anchors was shown to provide superior resistance to gap formation. These findings, alongside higher costs associated with DR repairs, suggest that SR repair remains a cost-effective and clinically robust option, particularly relevant for developing countries. Moreover, arthroscopy has been shown to detect subscapularis tears that may be missed on MRI or

Table 2: Clinical outcomes following arthroscopic rotator cuff repair.

S. No.	Outcome measure	Pre-operative (Mean±SD)	Post-operative (Mean±SD)	t-value	P-value
1.	Active forward flexion (°)	96.5±21.0	166.5±11.6	27.70	<0.001
2.	External rotation (°)	57.8±12.6	79.2±10.1	18.15	<0.001
3.	Visual analog scale (0-10)	7.3±1.1	1.2±0.8	33.22	<0.001
4.	Muscle strength score (0-25)	10.9±2.6	22.8±3.3	25.40	<0.001

SD: Standard deviation

Table 3: Functional scores stratified by rotator cuff tear size.

Tear size	CMS before surgery (0-100, Mean±SD)	CMS final follow-up (0-100, Mean±SD)	t-value (CMS)	P-value (CMS)	UCLA before surgery (0-35, Mean±SD)	UCLA final follow-up (0-35, Mean±SD)	t-value (UCLA)	P-value (UCLA)
Small	59.6±8.8	99.3±1.9	10.49	<0.001	22.9±2.4	35.0±0.0	13.33	<0.001
Medium	55.8±6.7	96.7±5.6	31.91	<0.001	21.9±3.3	33.9±1.8	22.14	<0.001
Large	50.3±11.4	85.5±9.4	9.07	<0.001	19.3±2.9	30.3±3.7	14.41	<0.001
Massive	50.0±0.0	100.0±0.0	–	–	25.0±0.0	35.0±0.0	–	–

UCLA: University of California, Los Angeles, CMS: Constant-Murley score, SD: Standard deviation

Table 4: Evaluation of functional outcomes in healed and re-tear cases.

Parameter	Sugaya type 1 (Mean±SD)	Sugaya type 2 (Mean±SD)	Sugaya type ≥3 (Mean±SD)	F-value	P-value
VAS (0-10)	1.02±0.62	2.16±0.75	2.33±0.58	14.10	<0.001
CMS (0-100)	97.06±5.21	82.67±9.42	81.33±6.35	25.54	<0.001
UCLA Score (0-35)	34.10±1.66	32.24±3.67	30.67±4.04	21.71	<0.001
Muscle Strength (0-25)	23.63±2.51	18.5±4.04	17.00±2.00	17.34	<0.001

VAS: Visual analog scale, UCLA: University of California, Los Angeles, CMS: Constant-Murley score, SD: Standard deviation

clinical examination, emphasizing its diagnostic value in comprehensive rotator cuff evaluation.^[15]

Impact of fatty atrophy and tear size

Our study supports prior findings that SR repair yields favorable results even in the presence of fatty muscle infiltration. Improvements in CMS and UCLA scores were observed in patients with Goutallier grades I-III atrophy, in line with Burkhart *et al.*,^[16] who advocated for repair irrespective of fatty degeneration when a tension-free construct can be achieved. Goutallier *et al.*^[17] emphasized that complete, tension-free repairs promote better healing through improved osseous integration, which was supported by our post-operative outcomes, even in large or massive tear cases.

US and structural healing

Post-operative tendon integrity was assessed using US and classified through the Sugaya grading system. In our cohort, 95% of patients achieved structural healing (Sugaya grades 1 or 2). Functional outcomes were significantly better in patients with healed cuffs, corroborating findings by Malavolta *et al.*^[18] and Sugaya *et al.*^[19] Yoshida *et al.*^[20] also noted that Sugaya grade correlated positively with muscle strength. While Galatz *et al.*^[21] reported a high incidence of structural failure (94%) after SR repair, our findings of only 5% re-tear at 2 years demonstrate favorable healing with modern surgical techniques and post-operative protocols. Russell's meta-analysis^[22] further supports that intact repairs are associated with superior strength and ROM.

Limitations and strengths

Strengths of this study include its relatively large sample size, a uniform surgical technique performed by a single experienced surgeon, and objective evaluation by independent assessors. Functional outcomes were evaluated using multiple validated scoring systems and correlated with tendon integrity assessed by high-resolution US.

Limitations include the retrospective design and potential selection bias, as only patients with complete follow-up at 24 months were included in the study. Functional and structural assessments were conducted only at the final follow-up, and intermediate healing dynamics were not captured. Future prospective studies with serial imaging and functional assessments may provide more granular insight into the timeline of tendon healing and functional recovery.

CONCLUSION

Arthroscopic SR-ARCR demonstrated significant clinical and structural improvements at the 24-month follow-up. Patients with structurally healed tendons, as assessed by US, showed superior muscle strength and functional outcomes compared to those with re-tears. Importantly, pre-operative factors such as fatty muscle atrophy and tear size did not

substantially impact post-operative recovery, suggesting that SR repair remains a reliable and effective option across a broad spectrum of full-thickness rotator cuff tears. These findings support the use of SR ARCR as a cost-effective and functionally robust technique in routine clinical practice.

Author contributions: JPJ: Concepts, definition of intellectual content, and design; SAS: Literature search, data acquisition, clinical studies, data analysis, and manuscript preparation; VVP: Data analysis, statistical analysis, manuscript preparation, manuscript editing, and review.

Ethical approval: The Institutional Review Board approval is not required since it was a retrospective study evaluating outcomes.

Declaration of patient consent: The authors certify that they have obtained all appropriate patient consent forms. In the form, the patients have given their consent for their images and other clinical information to be reported in the journal. The patients understand that their names and initials will not be published and due efforts will be made to conceal their identity, but anonymity cannot be guaranteed.

Financial support and sponsorship: Nil.

Conflicts of interest: There are no conflicts of interest.

Use of artificial intelligence (AI)-assisted technology for manuscript preparation: The authors confirm that there was no use of artificial intelligence (AI)-assisted technology for assisting in the writing or editing of the manuscript and no images were manipulated using AI.

REFERENCES

1. Van Der Meijden OA, Westgard P, Chandler Z, Gaskill TR, Kokmeyer D, Millett PJ. Rehabilitation after arthroscopic rotator cuff repair: Current concepts review and evidence-based guidelines. *Int J Sports Phys Ther* 2012;7:197-218.
2. Davey MS, Hurley ET, Carroll PJ, Galbraith JG, Shannon F, Kaar K, *et al.* Arthroscopic rotator cuff repair results in improved clinical outcomes and low revision rates at 10-year follow-up: A systematic review. *Arthroscopy* 2023;39:452-8.
3. Vecchini E, Ricci M, Elena N, Gasperotti L, Cochetti A, Magnan B. Rotator cuff repair with single row technique provides satisfying clinical results despite consistent MRI retear rate. *J Orthop Traumatol* 2022;23:23.
4. Veen EJ, Boeddha AV, Diercks RL, Kleinlugtenbelt YV, Landman EB, Koorevaar CT. The arthroscopic isolated long head of biceps tenotomy in patients with degenerative rotator cuff tears: Mid-term clinical results and prognostic factors. *Eur J Orthop Surg Traumatol* 2021;31:441-8.
5. Walch G, Edwards TB, Boulahia A, Nové-Josserand L, Neyton L, Szabo I. Arthroscopic tenotomy of the long head of the biceps in the treatment of rotator cuff tears: Clinical and radiographic results of 307 cases. *J Shoulder Elbow Surg* 2005;14:238-46.
6. Busconi BB, DeAngelis N, Guerrero PE. The proximal biceps tendon: Tricks and pearls. *Sports Med Arthrosc Rev* 2008;16:187-94.
7. Boileau P, Ahrens PM, Hatzidakis AM. Entrapment of the long head of the biceps tendon: The hourglass biceps--a cause of pain and locking of the shoulder. *J Shoulder Elbow Surg* 2004;13:249-57.
8. Kim YK, Jung KH, Kim JW, Kim US, Hwang DH. Factors affecting rotator cuff integrity after arthroscopic repair for medium-sized or larger cuff tears: A retrospective cohort study. *J Shoulder Elbow Surg* 2018;27:1012-20.
9. De Jesus JO, Parker L, Frangos AJ, Nazarian LN. Accuracy of MRI, MR arthrography, and ultrasound in the diagnosis of rotator cuff tears: A meta-analysis. *AJR Am J Roentgenol* 2009;192:1701-7.
10. Huang R, Wang S, Wang Y, Qin X, Sun Y. A systematic review of all-arthroscopic versus mini-open repair of rotator cuff tears: A meta-analysis. *Sci Rep* 2016;6:22857.
11. Severud EL, Ruotolo C, Abbott DD, Nottage WM. All-arthroscopic

- versus mini-open rotator cuff repair: A long-term retrospective outcome comparison. *Arthrosc J Arthroscopic Relat Surg* 2003;19:234-8.
12. Mazzocca AD, Millett PJ, Guancho CA, Santangelo SA, Arciero RA. Arthroscopic single-row versus double-row suture anchor rotator cuff repair. *Am J Sports Med* 2005;33:1861-8.
 13. Nicholas SJ, Lee SJ, Mullaney MJ, Tyler TF, Fukunaga T, Johnson CD, *et al.* Functional outcomes after double-row versus single-row rotator cuff repair: A prospective randomized trial. *Orthop J Sports Med* 2016;4:2325967116667398.
 14. Faulkner ND, Getelman MH, Burns JP, Snyder SJ. Regarding meta-analysis comparing single-row and double-row repair techniques in the arthroscopic treatment of rotator cuff tears. *J Shoulder Elbow Surg* 2014;23:182-8.
 15. Barlow JD, Everhart JS. Arthroscopic subscapularis repair through a single anterior portal. *Arthrosc Tech* 2017;6:e1593-8.
 16. Burkhart SS, Barth JR, Richards DP, Zlatkin MB, Larsen M. Arthroscopic repair of massive rotator cuff tears with stage 3 and 4 fatty degeneration. *Arthroscopy* 2007;23:347-54.
 17. Goutallier D, Postel JM, Gleyze P, Leguilloux P, Van Driessche S. Influence of cuff muscle fatty degeneration on anatomic and functional outcomes after simple suture of full-thickness tears. *J Shoulder Elbow Surg* 2003;12:550-4.
 18. Malavolta EA, Assunção JH, Andrade-Silva FB, Gracitelli ME, Kiyomoto HD, Ferreira Neto AA. Prognostic factors for clinical outcomes after arthroscopic rotator cuff repair. *Orthop J Sports Med* 2023;11:23259671231160738.
 19. Sugaya H, Maeda K, Matsuki K, Moriishi J. Functional and structural outcome after arthroscopic full-thickness rotator cuff repair: Single-row versus dual-row fixation. *Arthroscopy* 2005;21:1307-16.
 20. Yoshida M, Collin P, Josseaume T, Lädermann A, Goto H, Sugimoto K, *et al.* Post-operative rotator cuff integrity, based on sugaya's classification, can reflect abduction muscle strength of the shoulder. *Knee Surg Sports Traumatol Arthrosc* 2018;26:161-8.
 21. Galatz LM, Ball CM, Teefey SA, Middleton WD, Yamaguchi K. The outcome and repair integrity of completely arthroscopically repaired large and massive rotator cuff tears. *J Bone Joint Surg Am* 2004;86:219-24.
 22. Russell RD, Knight JR, Mulligan E, Khazzam M. Structural integrity after rotator cuff repair does not correlate with patient function and pain: A meta-analysis. *J Bone Joint Surg Am* 2014;96:265-71.

How to cite this article: Jesalpara JP, Shah SA, Patel VV. Functional and structural outcomes of arthroscopic single-row repair in full-thickness rotator cuff tears. *J Arthrosc Surg Sports Med.* 2026;7:30-5. doi: 10.25259/JASSM_20_2025